



# Department of Ophthalmology



New York  
Eye and Ear  
Infirmary of  
Mount  
Sinai





# Honoring Our Past, Envisioning Our Future

Founded in 1820



## CONTENTS

- 4 Message From the Department of Ophthalmology Leadership
- 6 NYEE Residents Sharpen Their Skills on Four Complex Cases
  - A Resident Draws on a Diverse Team to Address a Traumatic Eye Injury
  - A Rare Pathogen Turns Residents Into a Team of Medical Sleuths
  - A 31-Year-Old Man With Advanced Cataracts Puts a Third-Year Resident to the Test
  - A Delicate Orbitotomy Teaches Residents the Value of Persistence
- 16 Surgeons at NYEE and Mount Sinai Team Up for a Five-Year-Old Patient
- 20 Putting Quality, Safety, and Experience on a Pedestal
- 22 A New and Advanced Ambulatory Surgery Center Will Become Our Leading Edge of Transformation
- 24 Eye Plaque Radiation Therapy Preserves the Sight of Patients With Invasive Carcinoma
- 26 A New Industry Partner Is a Milestone for Ophthalmic Robotics
- 28 Helping Low-Vision Patients Lead Independent Lives
- 30 Looking for Macular Degeneration in All the Right Places
- 32 Unraveling the Wound-Healing Magic of the Corneal Epithelium
- 33 Researchers Target a Major Hurdle for Retinal Stem Cell Replacement
- 34 A New Study Finds Blacks Have More Advanced Visual Field Loss at First Diagnosis of Glaucoma
- 36 Uncovering Glaucoma's Vascular Link in People of African Descent
- 38 New Imaging Shows First-Time Evidence of Vaso-Occlusion Dynamics in Sickle Cell Disease
- 40 Two Powerful Imaging Tools Make Their Debut in the United States
- 42 Department of Ophthalmology at a Glance
- 43 Faculty News



# Message From the Department of Ophthalmology Leadership

Even as we were reimagining New York Eye and Ear Infirmary of Mount Sinai (NYEE) for a new era—advancing programs and initiatives that strengthen our traditional pillars of patient care, education, research, and innovation—the institution didn't skip a beat over the past year.

More than ever, our focus is on ensuring the safety of the care we deliver and enhancing the experience of not just our patients, but our physicians and staff as well. To that end, we have implemented a comprehensive Quality, Safety, and Experience initiative, encompassing both our downtown and uptown campuses. This new leadership structure will focus on making us even better in three core areas—quality, safety, and experience—which are imperatives for NYEE in the twenty-first century.

Another way we've enhanced patient experience is through our Low Vision Clinic, which, as described in more detail in this report, recently named its first full-time director to expand a rehabilitative service that is vital to, but often sorely lacking within, the community. The clinic's goal is to help patients preserve their remaining vision and remain as independent as possible through an expanding range of traditional and exciting new aids and devices, and by linking them with experienced organizations in the city for mobility and functional training.

No asset is more important to our technology platform than continued development of our robotic assistant for complex ophthalmic surgery, and here we took a significant step by forming a scientific collaboration with ZEISS Medical, a global technology leader in the field of optics. That partnership will accelerate the pace of microsurgical robotics innovation at NYEE as we prepare the first robotic module—for retinal microsurgical intervention—for clinical trials.

Artificial intelligence (AI) is an increasingly important platform for our scientists. Drawing on a rich library of image data sets, they continue to uncover new ways to detect and treat diseases like glaucoma and macular degeneration, with major population health

implications. One of our research teams, for example, has pushed the boundaries of glaucoma discovery by decomposing the visual field into its component parts to establish patterns that could predict an individual's chances of acquiring primary open-angle glaucoma (POAG) later on. From a trove of national cohort data, we have identified 14 different patterns associated with various degrees of risk, with people of African heritage shown to have the greatest risk of POAG. This breakthrough work emphasizes the need for widespread screening among this population to detect glaucoma before it reaches one of the advanced patterns our research has established.



We're particularly proud, too, of the work of our acclaimed scientist Alon Harris, MS, PhD, Professor of Ophthalmology and Vice Chair of International Research and Academic Affairs, Icahn School of Medicine at Mount Sinai, to understand the role that ethnicity plays as a major contributor to the pathophysiology of glaucoma, the leading cause of irreversible blindness in people of African descent. Dr. Harris and his team are now building on that research by integrating artificial intelligence and mathematical modeling with clinical data to determine how race, along with other factors, can increase the risk of glaucoma.

Finally, our unflagging attention to education through ongoing improvements to the country's largest academic training program continues to be integral to our brand of excellence. As highlighted in this report, resident trainees are constantly exposed to learning opportunities through a multiplicity of health care sites, patient populations, and pathologies across New York City that few other medical centers in the country can offer.


That determination across our institution to push the limits of what's possible is not only enhancing the level of care we're now able to provide, but is also raising the bar ever higher for what we're fully committed to deliver to patients, communities, and populations as we write the next chapter in the 200-year history of NYEE.



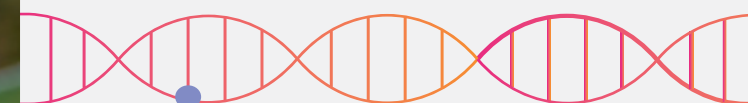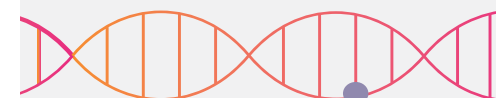**James C. Tsai, MD, MBA**  
President, New York Eye and Ear Infirmary of Mount Sinai  
Chair, Department of Ophthalmology, Icahn School of Medicine at Mount Sinai and Mount Sinai Health System



**Paul A. Sidoti, MD**  
Chair, Department of Ophthalmology, New York Eye and Ear Infirmary of Mount Sinai




**Louis R. Pasquale, MD, FARVO**  
Chair, Department of Ophthalmology, The Mount Sinai Hospital and Mount Sinai Queens



# NYEE

# Residents

## Sharpen Their Skills on Four Complex Cases



As New York Eye and Ear Infirmary of Mount Sinai (NYEE) continues to strengthen and expand its ophthalmology residency program—the largest accredited program of its type in the country—trainees are exposed to learning opportunities available at few other academic medical centers.

In 2021, for the first time, residents were able to rotate among four clinic and acute care sites throughout New York City that offer an extraordinary range of patients and ocular pathologies. Moreover, residents get to observe and actually perform parts of surgeries during their first year so that by their second year they are handling procedures from start to finish (under the watchful eye of an attending physician). “Accelerating the surgical process by a full year enables residents to function at a higher level during their first year, and represents a fundamental change in how we deliver residency training,” says Harsha S. Reddy, MD, Ophthalmology Residency Program Director and Site Director for Oculoplastics, Orbital, and Reconstructive Surgery at NYEE and Mount Sinai Beth Israel.

Paving the way for that restructuring is the Joint Internship Program launched in July 2020. The initiative allows trainees to start their residency enrolled in a one-year internship at Mount Sinai Beth Israel, which includes nine months of general medicine and three months of ophthalmology training. “Our Joint Internship Program gives us a small but important block of additional time to expose residents to our subspecialty clinics and to train them to perform the patient eye exam and treat emergencies,” notes Paul A. Sidoti, MD, Deputy Chair for Education, Department of Ophthalmology, Icahn School of Medicine at Mount Sinai, and Chair of Ophthalmology, NYEE. “It allows interns to truly hit the ground running when they begin their three-year residency.”

The four cases described on the following pages exemplify the complex procedures and pathologies that residents tackle. “What makes our program unique is that it allows residents to sharpen their surgical skills on cases that would be reserved for fellows or attendings elsewhere,” explains Dr. Reddy. “At NYEE, they’re not just observers, but actual surgeons who get to experience the complexities and teamwork that only a multispecialty eye hospital like New York Eye and Ear can offer.”

▶ cases begin on next page



# A Resident Draws on a Diverse Team To Address a Traumatic Eye Injury

Treating eye injuries day after day at New York Eye and Ear Infirmary of Mount Sinai's (NYEE) busy walk-in eye clinic in Manhattan has reinforced for Shravan Savant, MD, the role of triage in ensuring patients the best outcomes. Just how important a role was driven home again to the third-year ophthalmology resident by a 56-year-old man who entered the clinic one morning in March of 2021 after a 10 mm shard of metal from a machine shop penetrated his left eye, leaving him with intense pain and a traumatic wound in need of emergent care.

"With a complex case like this, the most immediate concerns are stabilizing the eye and triaging the patient in the most accurate and efficient way," says Dr. Savant. "My initial examination showed that the metal had pierced the patient's cornea and reached back to the lens, so I immediately made plans to send him to Mount Sinai Beth Israel for a CT scan to check for other metal fragments in the posterior segment. At the same time, I developed a plan for surgery as soon as he returned."

Given the nature of the wound, the No. 1 concern for Dr. Savant was infection, which could dramatically affect the outcome. "Apart from infection risk, a piece of metal in the retina is toxic, and can destroy vision very quickly," he explains.

Of more immediate concern for the patient, Jan Gilewski, a machine welder for New York City Transit, was the mounting pain. "I waited a bit, thinking it might go away, but when my vision became cloudy and the pain didn't let up, I told my supervisor and we drove across the bridge to the clinic at New York Eye and Ear," he recalls.

He was met by Dr. Savant, who soon began administering abundant amounts of antibiotic eyedrops, intravenous antibiotics, and tetanus vaccine to control the threat of infection. Meanwhile, the results of the CT, which arrived within an hour, showed the back of the patient's eye to be free of any metal. With that welcome news, Dr. Savant and the voluntary attending, Luna T. Xu, MD, Assistant Clinical Professor of Ophthalmology, NYEE, began surgery late that afternoon. "The prognosis is always guarded when you have a large foreign body removal like this one," explains Dr. Savant. "Even after the object is removed and the wound

is closed, the patient faces the prospect of astigmatism, and vision out of the eye may never be as good as it originally was."

When first attempts to push the object out by enlarging the wound opening proved unproductive, the surgeons used retinal forceps to snake the metal out from the front. That tactic allowed them to better assess the damage, and they learned that the force of the shard entering his eye had shattered its natural lens, triggering a traumatic cataract that precluded traditional lens removal. The capsule of the lens had split into the dreaded "Argentinian flag" configuration, preventing the normal techniques for capsulotomy. Instead, the surgeons used a technique known as a can opener capsulotomy in which they etch a circular series of tiny nicks in the anterior capsule surrounding the lens using a cutting instrument known as a cystotome, creating an opening to remove the cataract.

With the cataract removed, the next challenge confronting Dr. Savant and Dr. Xu was selection and placement of a new intraocular lens. Once again this called for extraordinary measures since the foreign body protruding into the eye had damaged the capsular bag, the normal support structure for the lens. Instead, the team implanted a three-piece acrylic lens in the sulcus in front of the bag. That still left another critical step: repairing the gaping hole in the cornea where the metal had entered by suturing it closed.

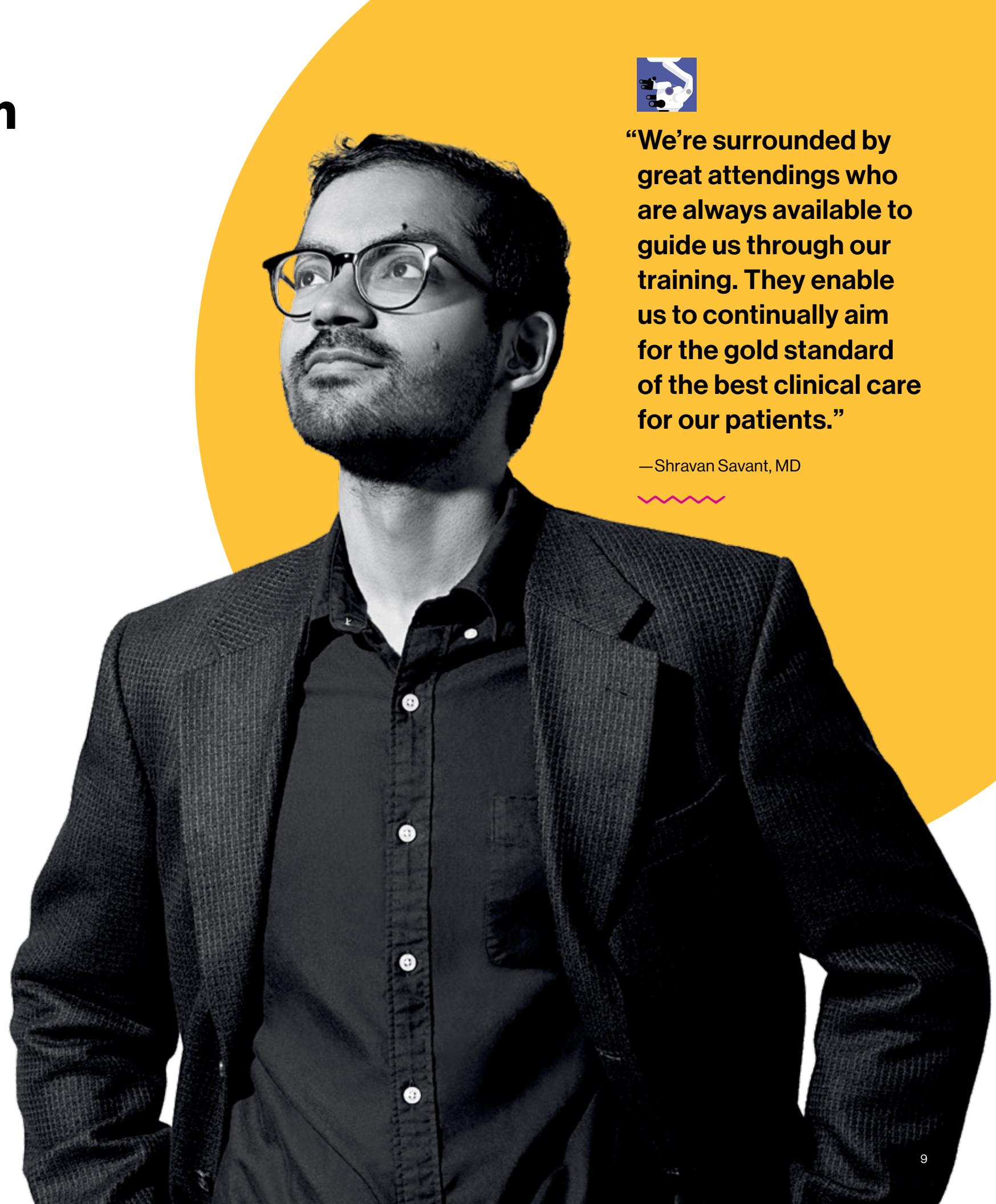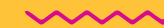The patient's vision out of the injured eye improved to 20/50 within the first few days, and to nearly 20/20 within 10 days, with no signs of infection. "He's actually seeing better out of his left eye than the other, which we never expected," reports Dr. Savant. "It shows what's possible when you get the entire team involved, from radiology to our retina specialists to our on-call trauma attendings. We did everything by the book, and it resulted in an excellent outcome."

The patient would be the first to agree. "I knew NYEE was the best eye clinic in the city, and Dr. Savant confirmed that for me," says Mr. Gilewski. "He dropped everything he was doing to focus on my case from the moment I walked in. He told me he would do everything he could to save my eye, and he certainly kept his word."



**"We're surrounded by great attendings who are always available to guide us through our training. They enable us to continually aim for the gold standard of the best clinical care for our patients."**

—Shravan Savant, MD







**“Communication between team members is particularly important in cases where residents are seeing a patient almost every day.”**


—Jorge Andrade Romo, MD



Jorge Andrade Romo, MD



Jeanette Du, MD



# A Rare Pathogen Turns Residents Into a Team Of Medical Sleuths

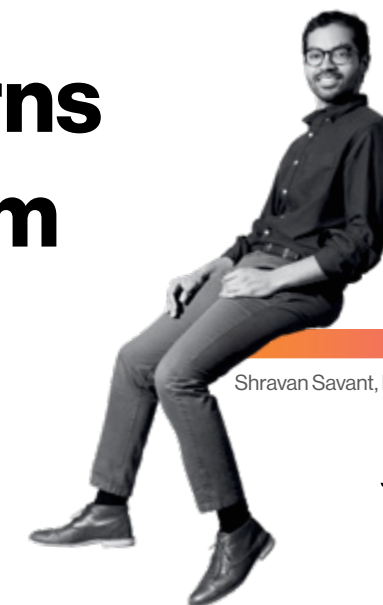
Bacterial infections are common fare for residents who staff New York Eye and Ear Infirmary of Mount Sinai’s (NYEE) comprehensive clinic. But when a young patient walked through the door in November 2020 with an infection so rare there were only two cited cases in the medical literature, it presented a unique opportunity for these ophthalmologists-in-training to learn about a new opportunistic pathogen and how to treat it.

The patient was an 11-year-old sixth grader, Chloe Corvino. She was referred to NYEE by Gaurav Chandra, MD, an ophthalmologist in her Westchester County hometown, after he noticed a serious infectious ulcer on the cornea of the right eye. “She was in intense pain and needed a clinic that could handle this type of pathogen with appropriate culturing and administration of fortified antibiotics,” says Dr. Chandra. NYEE, where he had completed his own fellowship in uveitis and ocular immunology, was the obvious choice.

The young patient was examined on a Saturday morning by Jeanette Du, MD, a first-year resident at the time. “This was an unusual case for me because it involved a child,” she notes. “But being a resident at a huge referral center like New York Eye and Ear, I had already seen a fair share of infections, and was comfortable doing the culturing to determine its etiology and starting the patient on antibiotics.”

Just as importantly, Dr. Du began communicating with the rest of the diverse team that would coalesce around the patient in the weeks of treatment to follow. These members included fellow residents Jorge Andrade Romo, MD, and Shravan Savant, MD, and specialists from NYEE’s Pathology, Pharmacy, and Corneal Services.

The turning point in the case was the return days later of the cultures from the microbiology lab. They showed that the soupy-looking 4 x 4.2 mm ulcer on the central cornea was not some typical bacterial infection, but an extremely rare fungal infection known as *Rhodotorula mucilaginosa*. Dr. Romo’s research found it to be a yeast organism of eastern Indian origin of which only 43 cases worldwide were reported between 1960 and 2000. It had somehow found its way to the suburbs of New York and into the eye of Chloe, a contact lens wearer, possibly through hot tub exposure.



Shravan Savant, MD



That revelation dramatically altered the treatment. Acting on very limited available research, the team, which included Anita Gupta, MD, Director of the Cornea Service at NYEE, decided on a systemic antifungal treatment of amphotericin B (0.15%) around the clock, eventually adding the topical medication vericonazole (1.0%). “We told the parents that we needed to switch to more robust medications, which we thought could deliver better results, but that these antifungal medicines also carried greater systemic risk,” says Dr. Savant, now a third-year resident who headed up the treatment team. “We also informed them that the visual prognosis in cases with this level of infection is guarded. We couldn’t be sure how much vision the patient would get back, and that the worst outcome could have been complete loss of vision.”

Within a week, the results began to crystallize. Chloe went from light perception only in the affected eye before the antifungal medicines to 20/70. “From the moment she was able to read letters on the wall chart, as they got smaller and smaller, we knew we were seeing incredible results,” beams Dr. Savant, who will soon begin a retina fellowship at Beth Israel Lahey Hospital and Medical Center in Massachusetts. The patient is not out of the woods yet: residual scarring on the surface of the eye could eventually require a corneal transplant. But for now, Chloe’s right eye vision is 20/25, enabling her to pursue a normal routine of classes and after-school lacrosse and field hockey.

“The doctors at New York Eye and Ear Infirmary were truly Chloe’s guardian angels,” says Chloe’s mother, JoAnne Corvino. “They were kind and patient and thoroughly explained everything to our frightened 11-year-old daughter. They were fully committed to helping her and I don’t believe we would have gotten the results we did if we had gone anywhere else.”



# A 31-Year-Old Man With Advanced Cataracts Puts a Third-Year Resident to the Test

When third-year ophthalmology resident Tommaso Vagaggini, MD, examined a 31-year-old man—the same age as Dr. Vagaggini—with advanced cataracts in both eyes, his training at New York Eye and Ear Infirmary of Mount Sinai (NYEE) instantly kicked in.

“We see a lot of cataracts at our eye walk-in clinic, but rarely ones this dense or hydrated, especially in someone this young,” recalls Dr. Vagaggini. “It made me think diabetes could be the underlying cause.”

A simple finger-stick blood sugar test done on the spot confirmed his suspicion: the patient’s glucose level was through the roof at 465 mg. He was immediately sent to the emergency room at nearby Mount Sinai Beth Israel (MSBI) in downtown Manhattan, where he remained for three days as an endocrinology team began an aggressive program to get his type 2 diabetes under control—a critical step before addressing his cataracts.

“I was really scared when I got the diagnosis,” says the patient, Luis Riollano. “It never crossed my mind that I might have diabetes, or cataracts at my age.”

What he did know was that something was seriously wrong with his sight. An eyeglass wearer, he said his vision had become so cloudy by late summer 2021 that he was reduced to seeing shadows and shapes only. He was forced to leave his job, and even a trip to the grocery store turned into a navigational challenge. Thinking a simple change in prescription might be the solution, he went to an optometrist in his Brooklyn neighborhood, who informed him he had cataracts and referred him to NYEE.

Under the care of endocrinologist John Graham, MD, PhD, and his team at MSBI, Mr. Riollano steadily improved with insulin injections and a rigorous diet. Dr. Vagaggini closely monitored his progress, and was assured in early December by Dr. Graham that the patient’s blood sugar was now under control, making it possible to proceed with ophthalmic surgery.

That intervention presented its own set of challenges—and another unique learning experience—for Dr. Vagaggini. Because

the patient’s cataracts were so large and dense, surgeons were unable to see what other pathology was present in the back of the eye. Just as concerning was the stress those cataracts were causing to the capsular bag—the thin membrane around the eye’s natural lens. “When a bag is under that much pressure, it stretches, and during cataract surgery, you run the risk of the membrane splitting open uncontrollably and causing a posterior capsule break, as well. That’s a very serious surgical complication.”

Fortunately for Dr. Vagaggini and the attending on the case, Robyn Horowitz, MD, a voluntary clinical instructor with NYEE, the lens capsule remained intact even after the initial anterior opening was made, allowing them to begin the delicate task of removing the cataract from the anterior chamber of the patient’s left eye through phacoemulsification. That prompted other critical decisions: what type of intraocular lens (IOL) to implant, and where to place it. “When you have a capsular bag that unstable, placing a lens inside could be a recipe for disaster,” explains Dr. Vagaggini. “So we decided to use a three-piece IOL and implant it in front of the bag, in the sulcus, the space between the posterior surface of the iris and the anterior surface of the capsular bag.”

Despite the challenges, the surgery on December 7, 2021, went well, as evidenced by the patient’s vision the next day. “I was able to see better out of my left eye than ever before,” Mr. Riollano beams. The second cataract surgery three months later—a more conventional procedure without the drama of the first—left the patient even more ecstatic. “I was really amazed—the doctors gave me 20/20 vision out of both eyes without glasses,” he says. “I had always been afraid of doctors, but this experience completely changed me. Dr. Vagaggini went above and beyond, even giving me his personal phone number.”

Dr. Vagaggini professes to be as excited about the outcome as the patient. “I was immensely satisfied to know that someone only 31 years old is now able to return to a normal life with no limitations. For me, that’s the most wonderful part about being a physician.”



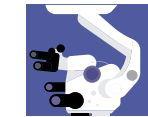
**“As a resident at New York Eye and Ear, I’m given the independence to see and guide patients through their journey and establish close bonds with them as their physician. That’s an incredible part of my training because it gives me the confidence to take on increasing responsibility.”**

—Tommaso Vagaggini, MD



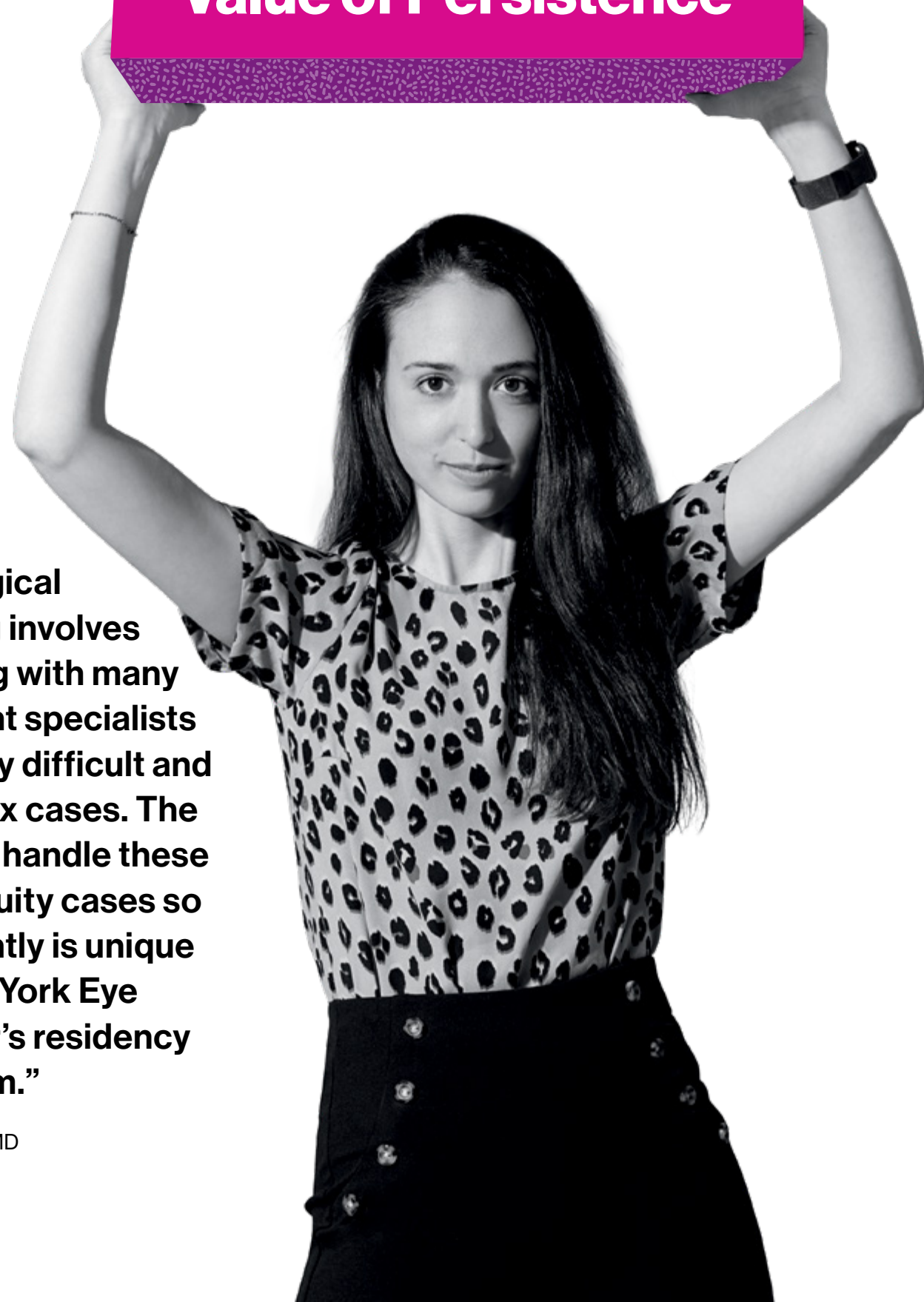
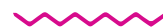
# A Delicate Orbitotomy Teaches Residents the Value of Persistence



**“My surgical training involves working with many different specialists on really difficult and complex cases. The fact we handle these high acuity cases so frequently is unique to New York Eye and Ear’s residency program.”**

—Bella Wolf, MD



Most ophthalmology residents in medical schools nationwide never see a cavernous hemangioma, a sight-threatening orbital tumor characterized by bulging and displacement of the eye. When third-year New York Eye and Ear Infirmery of Mount Sinai (NYEE) resident Bella Wolf, MD, became part of a team performing a three-hour orbitotomy on a 43-year-old female patient, it taught her a valuable lesson about the importance of discipline and perseverance during these extremely delicate surgical procedures.

“There were times during the surgery I thought we were never going to find the tumor, it was embedded so deeply in the retro orbital area behind the eye,” she recalls. But observing firsthand the determination and patience of the attending on the case, Harsha S. Reddy, MD, Site Director for Oculoplastics, Orbital, and Reconstructive Surgery at NYEE and Mount Sinai Beth Israel and Director of the Ophthalmology Residency Program, convinced her of the need to “never let up until you’ve reached the goal of giving your patient the best outcome possible.”

That goal is more challenging than ever in the case of cavernous hemangiomas, where surgeons must typically operate in extremely tight spaces near the optic nerve. What’s more, this type of benign tumor—consisting of tightly packed thin-walled capillaries—can hemorrhage during surgery, risking blood supply to the optic nerve and other critical structures of the eye and eye socket.

When the patient was referred to NYEE by an outside ophthalmologist in late October 2021 with severe proptosis (in excess of 8 mm) of the right eye, physicians immediately suspected that a mass behind the eye was responsible for the bulging. An MRI confirmed the diagnosis: a right orbit intraconal tumor (2.5 x 2.2 x 1.7 mm) was causing displacement of the optic nerve, suggesting a noncancerous orbital lesion. Another sign was the patient’s vision, which had decreased to 20/125 and would certainly get worse—with complete loss of sight a possibility—without removal of the tumor.

The minimally invasive orbitotomy began late on a Friday afternoon, with Dr. Wolf and second-year resident Mona Fayad, MD, joining Dr. Reddy for the procedure. Gaining access to the deeply entrenched mass, which was abutting the optic nerve and pushing it upward, was the most trying part of the lengthy procedure for the residents. The surgical team began with a tiny incision below the corner of the eye; they then loosened the bottom part of the eyelid from its attachment to the bone and dissected downward through the conjunctiva to reach the retro orbital area. “The tumor evaded us by burying itself among the surrounding tissue,” explains Dr. Fayad. “That’s where Dr. Reddy’s calm and motivating manner kept us moving forward, until we found a way to remove it in one piece.”

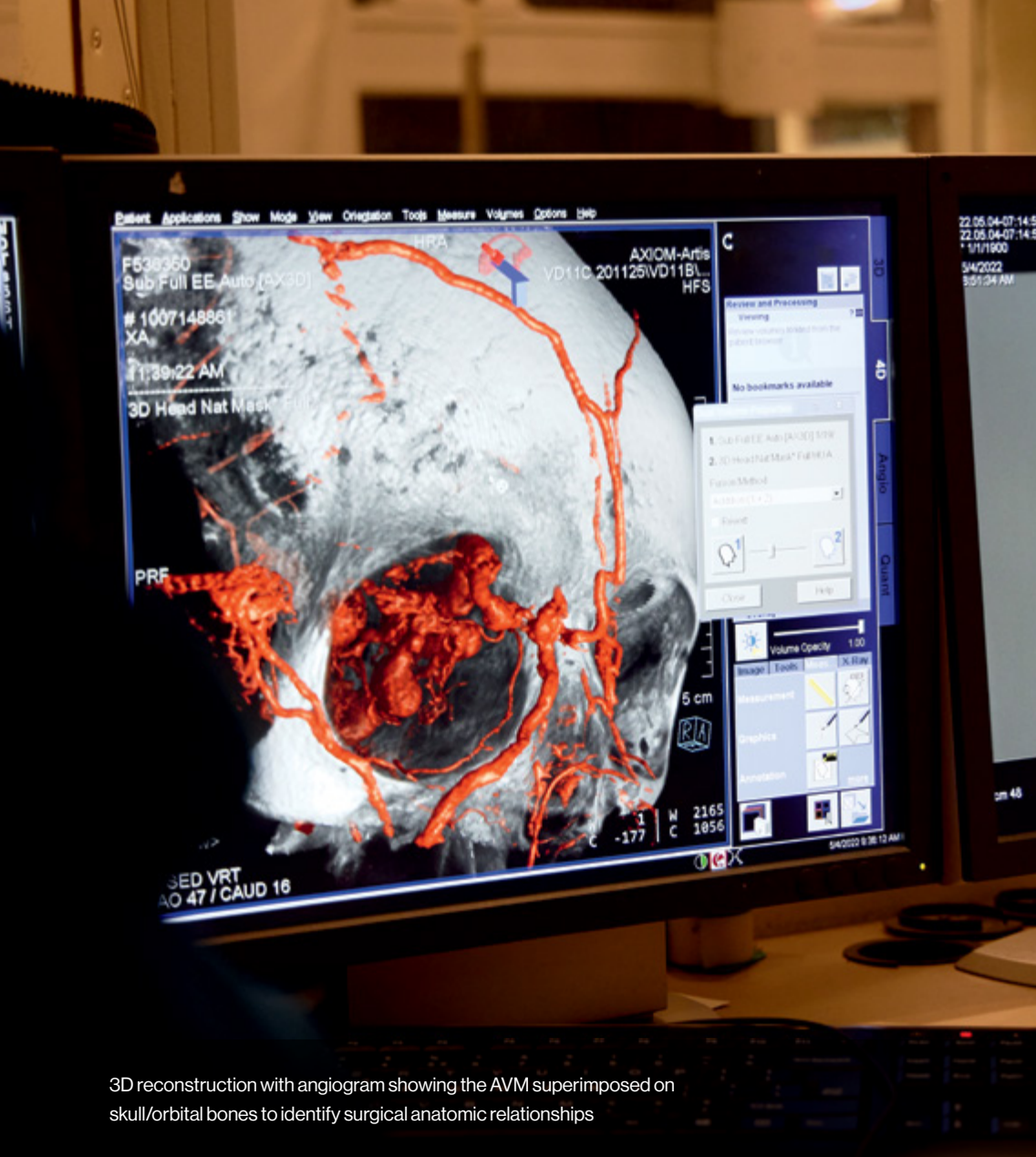
The next challenge for the surgeons was removing the tumor without rupturing its fragile walls and triggering a loss of blood that could have been catastrophic for the eye. Here the residents learned the advantages of multiple techniques—including blunt dissection, traction sutures, and cryotherapy—to slowly pull the tumor out in one piece. Dr. Wolf, who will soon begin a cornea fellowship at the University of Illinois, remembers the meticulous process as “an amazing feat that extracted the tumor without disrupting it, and left the patient with a barely visible scar beneath her eye.” The success of the procedure became more evident in the days that followed, when the patient’s vision in her right eye improved to 20/25, coupled with a favorable prognosis for normal vision out of both eyes.

“As residents, we see a lot of complex cases here, but this one took us to a different level,” stresses Dr. Fayad. “It showed us the importance of tactful preoperative planning, sheer determination, and expert supervision, which happen to be the fundamentals of our training at NYEE.”

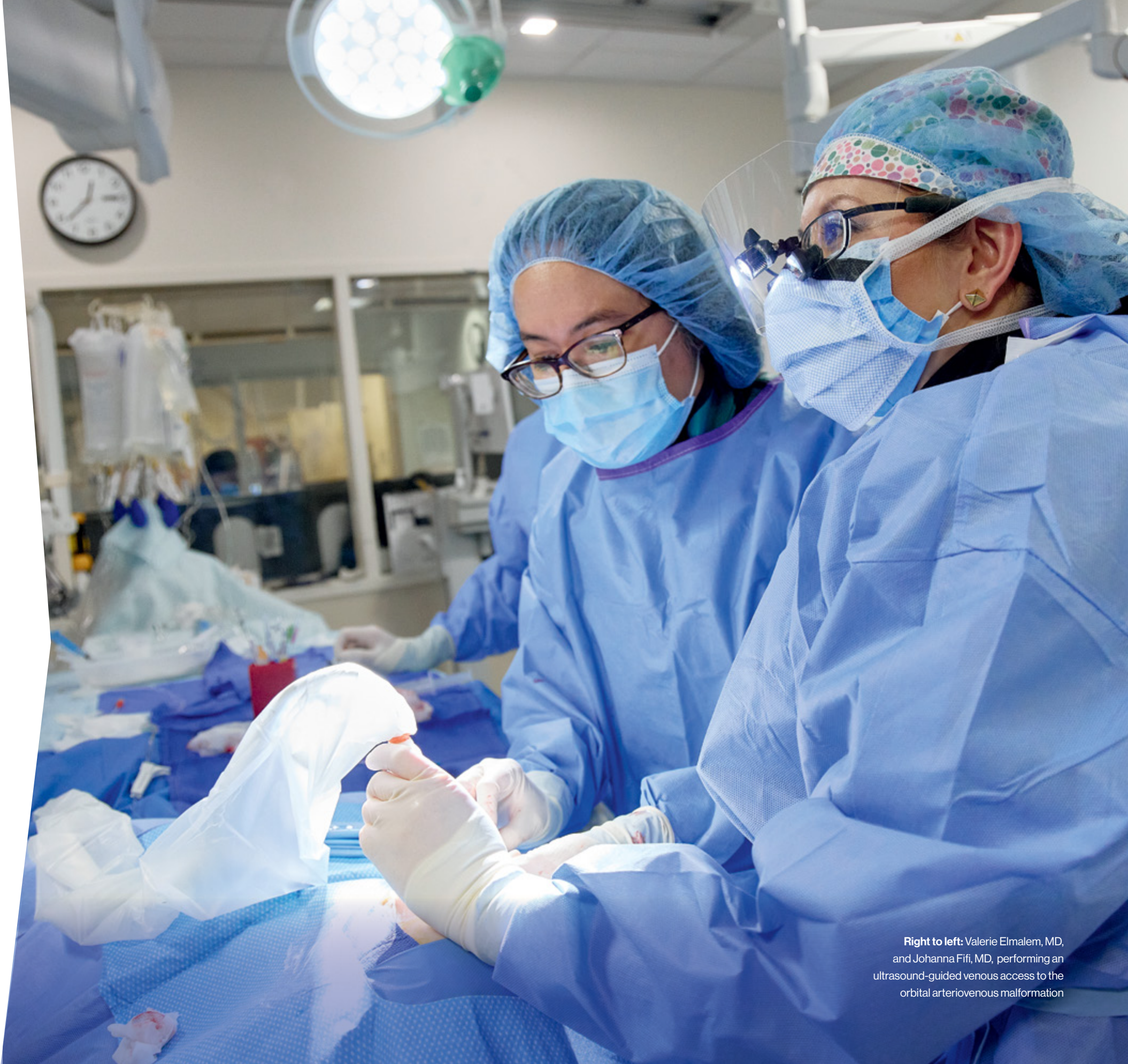

Mona Fayad, MD





3D reconstruction with angiogram showing the AVM superimposed on skull/orbital bones to identify surgical anatomic relationships



Right to left: Valerie Elmalem, MD, and Johanna Fifi, MD, performing an ultrasound-guided venous access to the orbital arteriovenous malformation

# Surgeons at NYEE And Mount Sinai Team Up for a Five-Year-Old Patient

> continued



Recent surgery to repair an arteriovenous malformation (AVM) in the orbit compressing the optic nerve of a five-year-old boy showed the benefits of combining the specialized skills and technical resources of New York Eye and Ear Infirmary of Mount Sinai (NYEE) and the Mount Sinai Health System.

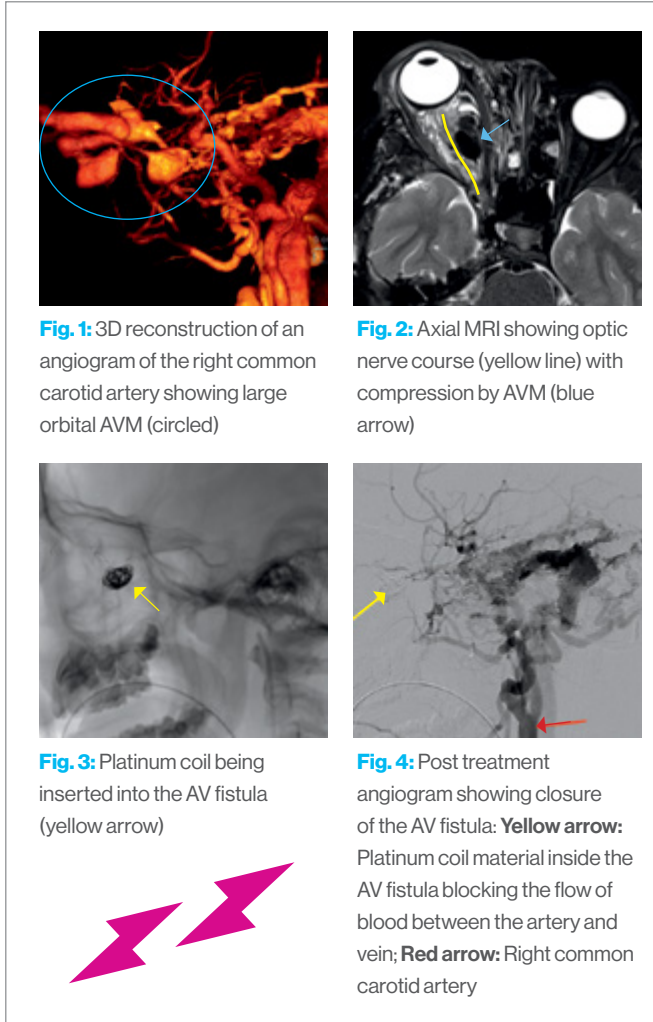
In the four-hour procedure at The Mount Sinai Hospital, an NYEE oculoplastic surgeon provided difficult intravascular AVM access for the neuro-endovascular team at Mount Sinai, with the help of a sophisticated 3D fluoroscopy-guided angiography system and ultrasonography.

“These cases are so complex that you really need a multidisciplinary team to reach the malformation and effectively treat it,” says Valerie I. Elmalem, MD, Associate Professor of Ophthalmology at the Icahn School of Medicine at Mount Sinai and a neuro-ophthalmologist and oculoplastic surgeon at NYEE, who teamed up with Johanna Fifi, MD, Associate Director of the Cerebrovascular Center at Icahn Mount Sinai, on the procedure. The patient is doing well postoperatively despite a host of challenges that pushed the surgeons to their limits, which underscores the synergies possible through joining the skill sets of two acclaimed medical centers.

The young patient, Bryson Hadden, faced a welter of issues. From birth, he developed AVMs and venolymphatic malformations in various regions of the head. When his right eye began bulging in August 2021—a condition his mother, Brittany Hadden, recalls as “really nasty-looking and painful”—an MRI and magnetic resonance angiography revealed an intra-orbital arteriovenous as well as multiple intracranial arteriovenous malformations. This tangle of blood vessels, also known as a fistula, forms abnormal connections between arteries and veins, and the resultant expansion of the previously small, low-flow veins compresses the surrounding tissues. It also runs the risk of rupturing and causing massive bleeding.

A referral from Bryson’s ophthalmologist to Mount Sinai set in motion a series of surgical interventions. In January, Dr. Fifi treated an intracerebral malformation, detecting at the time the new orbital malformation that was compromising the patient’s eyesight. But she also realized that intra-arterial access to the AVM—needed to perform standard coil embolization—would require an extra set of specialized hands.

“Normally, when we treat these kinds of malformations, we go through the jugular to get access to the vein, but in this patient’s case, that route was occluded, so we had to directly puncture the vessel by the orbit,” explains Dr. Fifi, who had joined forces with Dr. Elmalem on a previous surgery. “That’s when I asked



**Fig. 1:** 3D reconstruction of an angiogram of the right common carotid artery showing large orbital AVM (circled)

**Fig. 2:** Axial MRI showing optic nerve course (yellow line) with compression by AVM (blue arrow)

**Fig. 3:** Platinum coil being inserted into the AV fistula (yellow arrow)

**Fig. 4:** Post treatment angiogram showing closure of the AV fistula: **Yellow arrow:** Platinum coil material inside the AV fistula blocking the flow of blood between the artery and vein; **Red arrow:** Right common carotid artery

Dr. Elmalem to get involved. As an oculoplastic surgeon, she has the ability to get direct surgical access to the veins in the orbit.”

It proved to be anything but routine surgery, however. “All of us were very nervous about this case because of all the important blood vessels that were connecting to the ophthalmic artery,” says Dr. Elmalem. “If a clot were to form and travel through the artery, the patient would go blind.” Another challenge was the patient’s age—a rambunctious five-year-old who is also on the autism spectrum. The usual access to the vein through the orbit could have led to difficult-to-manage vision-threatening postoperative bleeding from the child rubbing his face or eyes.

Dr. Elmalem’s solution was to avoid any incision by gaining access from the face, through one of the dilated vessels that ran medial to the orbit. While the strategy was sound, its execution proved onerous. Every effort to advance a microcatheter through a facial puncture into the vein to allow treatment of the fistula through coil embolization was met with resistance. “We kept trying different areas of the face, and after



Bryson with his mom and dad at Stuyvesant Square Park following his third postop visit with Dr. Elmalem in July 2022

an hour and a half were finally successful by going through the angular vein that runs between the side of the nose and inner corner of the eyelid,” explains Dr. Elmalem. That cleared the way for Dr. Fifi and her team to close off the faulty connection between vein and artery with a metallic occluding coil.

Integral to the delicate surgery was a sophisticated neuro-navigational system at Mount Sinai that NYEE was able to tap into. Specifically, the hospital’s fluoroscopy-guided angiography allowed both teams of surgeons to pinpoint the precise location of the fistula—where the artery connects to the venous pouch—going well beyond just the bony structure normally seen by Dr. Elmalem in her orbital surgery. Throughout the procedure, this technology provided vital 3D guidance to surgeons—including viewing the coils entering the fistula—from their monitors.

Postsurgically, Bryson has continued to make progress. Closing the fistula in the right eye produced a change in his vision from 20/200 to 20/80, with further improvements expected as the left eye is patched for increasingly longer periods to treat his amblyopia.


**“These cases are so complex that you really need a multidisciplinary team to get at the malformation and effectively treat it.”**

—Valerie I. Elmalem, MD



“Bryson is always happy, and his problems haven’t held him back in school,” says his mom. While the family’s three-hour trips from their home in upstate New York to Manhattan for treatment are demanding, she calls them “well worth the time given the high-quality care Bryson is receiving” from the doctors at Mount Sinai and NYEE.





# Putting Quality, Safety, and Experience On a Pedestal

As it reconfigures its practice for the future, New York Eye and Ear Infirmary of Mount Sinai (NYEE) is drawing generously on its pandemic-driven experience of the past. That has resulted most prominently in the creation of a Quality, Safety, and Experience initiative with the mandate from leadership to standardize across all NYEE sites meaningful improvements in how we respond to the needs of our patients as well as our physicians and staff.

“The pandemic demonstrated to us the synergies that are possible through a coordinated approach to ensure the best experience for everyone, from patients to clinicians,” says Gareth M. C. Lema, MD, PhD, the new Vice Chair for Quality, Safety, and Experience at NYEE, and Associate Professor of Ophthalmology, Icahn School of Medicine at Mount Sinai. “I’ll be working closely with medical directors at major sites and satellite offices across the Mount Sinai Health System to build on that momentum.”

Dr. Lema is well equipped for the challenge. Since joining NYEE three years ago, he has served (in addition to his clinical responsibilities) as Site Director for Quality, Safety, and Experience at The Mount Sinai Hospital, and as the departmental faculty well-being champion. In these roles, he has been part of teams focused on developing and implementing COVID-19 protocols—including masking, patient spacing in waiting areas, and cleanliness—across the entire Health System.

“Our commitment to quality, safety, and experience has always been central to our practice,” emphasizes Paul A. Sidoti, MD, Chair, Ophthalmology, NYEE, and part of the NYEE leadership team that will work closely with Dr. Lema in this field. “What’s changed is our formalization of the program to stimulate new ideas and strategies, and ensure new initiatives have the resources and impetus to succeed.”

That movement has already gained considerable traction, as illustrated by our leading-edge work in the field of disinfection, which intensified during the pandemic. As Dr. Lema points out, instruments that contact the surface of the eye—including lenses for eye exams, tonometer tips, and therapeutic lasers—require high-level disinfection (HLD) to meet the recommendations of the Joint Commission and the American Academy of Ophthalmology. In most hospital settings, these instruments are cleaned at a central processing site, or disposable lenses (often of inferior quality) are used. NYEE developed an inexpensive and efficient method of HLD that provides for disinfection of multiple ocular lenses and tonometer tips. “This system has allowed us to maintain our own lenses, thereby preventing loss and damage while providing the highest standards of quality and safety around our instruments,”

**“Our commitment to quality, safety, and experience has always been central to our practice.”**

—Paul A. Sidoti, MD

explains Dr. Lema, who wrote many of the safety protocols during the pandemic.

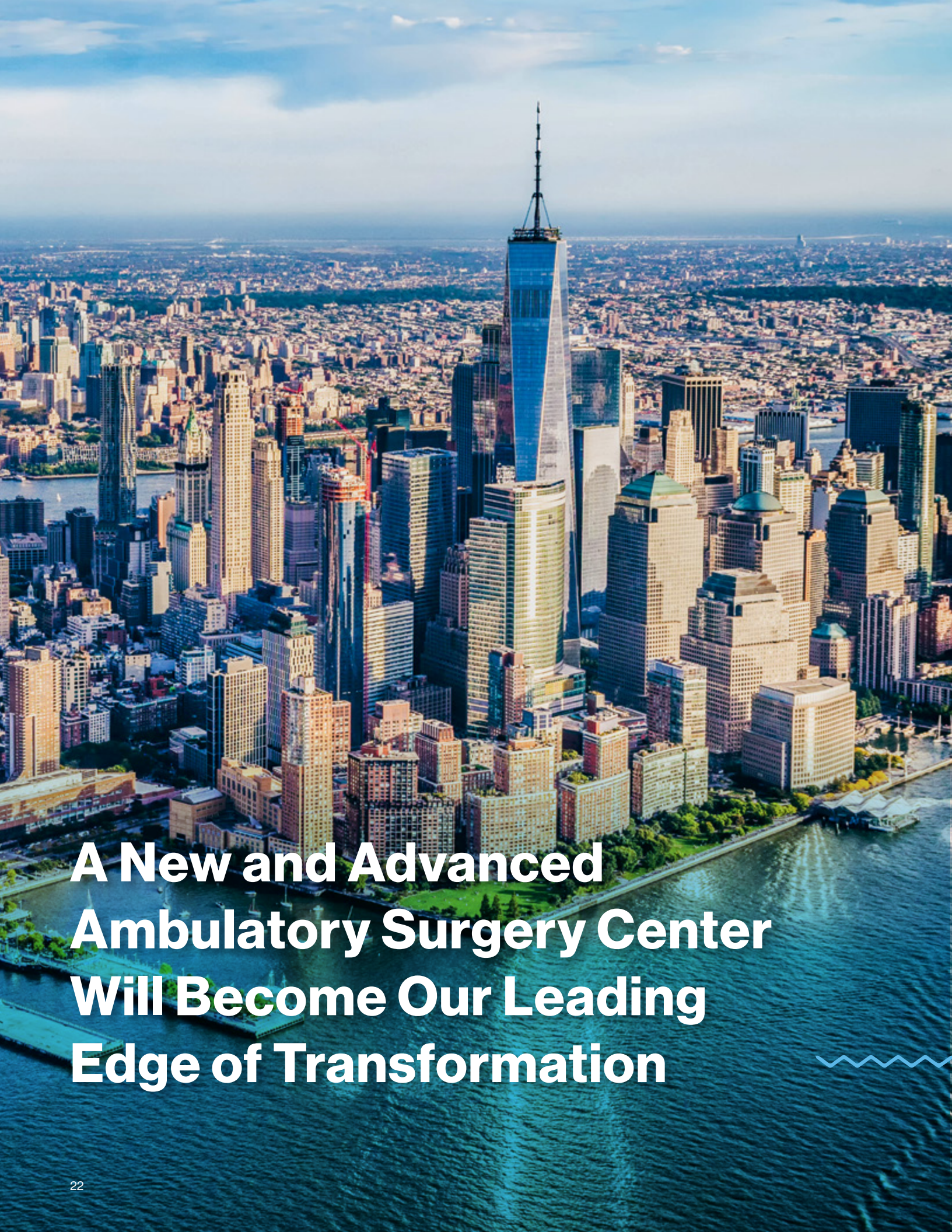Another initiative that Quality, Safety, and Experience will work to standardize based on its overwhelming success during COVID-19 is teleophthalmology. “If patients don’t have to visit one of our offices to confer with their physician, it decreases their health risk, while providing the convenience of a service they’re extremely happy with,” observes Dr. Lema, who will coordinate expansion of the platform to benefit both physicians and patients.

To that end, one effort well underway is the electronic linkage of retinal specialists with emergency room physicians who are challenged with treating, in a tight window, patients with central retinal artery occlusion (CRAO), or eye stroke. The teleconsultation program has already dramatically reduced the time it takes to diagnose and treat CRAO by strategically locating optical coherence tomography scanners at three busy Mount Sinai hospitals. Members of the Mount Sinai stroke team have been trained to use this equipment to assess patients with suspected CRAO and, once the images are collected, to upload them to retina specialists at NYEE for immediate review and remote consultation at the point of care.

That novel initiative is serving as a model for development of a teleconsultation service aimed at triaging and treating a far broader range of ophthalmic emergencies that short-staffed hospitals must routinely handle. The teleconsult strategy is also being deployed at primary care offices within Mount Sinai to screen patients for diabetic retinopathy. Plans call for adding artificial intelligence to the equation for on-site image interpretation so patients could be alerted to potential problems before they even leave the primary care office.

In his expansive new role, Dr. Lema will be a pivotal player in many of these forays. “It’s more important than ever that we have a collaborative effort to bring the various clinicians and strategies together,” he asserts. “That’s really how we put quality on a pedestal so that it’s of greatest value to patients and enhances the ability of physicians to do their jobs.”





# A New and Advanced Ambulatory Surgery Center Will Become Our Leading Edge of Transformation

A bold blueprint to transform New York Eye and Ear Infirmary of Mount Sinai (NYEE) into a model health care system more in tune than ever with the rapidly changing needs of patients, technology, the community, and its physicians continues to make significant strides, underscored by plans to open the state-of-the-art New York Eye and Ear of Mount Sinai Ambulatory Surgery Center (ASC) near Madison Square Park in Midtown Manhattan in the fall of 2023. An NYEE-branded joint venture facility, the new ASC reflects a partnership between NYEE, Mount Sinai Ambulatory Ventures (a subsidiary of Mount Sinai Health System), our community physicians, and Merritt Healthcare.

Like a host of other physical changes underway at NYEE, the ASC will bring the institution's 200-year-old brand of ophthalmic excellence and the highest levels of quality care to a modern facility designed to handle the majority of surgical procedures we perform, in a way that's most convenient and accommodating to both patients and surgeons.

"Our focus is on meaningful change to become more what state-of-the-art health care looks like—and where it's headed—in the twenty-first century," says James C. Tsai, MD, MBA, President of NYEE and Chair of Ophthalmology at the Icahn School of Medicine at Mount Sinai and the Mount Sinai Health System. "The new ASC is a critical part of that transformation by migrating many of our surgical procedures from the hospital to the community, and significantly enhancing the patient experience within a smaller and more intimate setting."

Driving the industry-wide change is a constellation of factors impacting the delivery of patient care—factors that are requiring health care providers to rethink and reconfigure their traditional models. Among those influencers are site-neutral payments, the growing insurance-inspired movement to pay the same amount for a service or procedure whether it's rendered in an ambulatory surgery center or a hospital. The COVID-19 pandemic also continues to impact the quality and character of health care, challenging providers to be more agile and creative in how they respond to health care disruptions. And NYEE's own future is being shaped by the paramount importance the Mount Sinai Health System has assigned to serving entire populations and to health care equity as vehicles for ensuring that all individuals have access to the same quality of care.

While these new imperatives are consistent with our centuries-old mission, they mean planting even

broader and deeper roots in the community. The ASC, to be located at Broadway and 25th Street, will be uniquely equipped to meet that goal. "In addition to modernizing our facilities, we know we have to make them more accessible and open to our patients by spreading our footprint beyond our downtown campus to sites across the city," explains Dr. Tsai. "The ASC will be a centrally located, high-visibility site with a strong commitment to assembling a talented team of physicians, surgeons, nurses, anesthesiologists, and technicians—like those located in our main hospital downtown—who have earned a national reputation for their commitment to clinical excellence."

Indeed, the evolving blueprint calls for co-locating NYEE's large faculty practice of clinicians in the same building as the ASC. Under the same roof will also be the Shelley and Steven Einhorn Clinical Research Center at NYEE, the centerpiece of our institution's cutting-edge research and clinical trials program. And at a nearby remodeled facility on Second Avenue and 22nd Street will be NYEE's resident-staffed eye clinic, relocating from its longtime home at our 14th Street hospital campus. Sharing the new site will be the Jorge N. Buxton, MD, and Douglas F. Buxton, MD, Microsurgical Education Center, one of the largest and most advanced training labs in the country.

Ensuring this expanding network of sites and services is tightly connected while maintaining unwavering quality will admittedly pose a challenge—but also an opportunity—for NYEE. "Changes will certainly need to occur in how we've done things in the past, when our culture was centered on a single building," allows Paul A. Sidoti, MD, Chair, Ophthalmology, NYEE. "But that culture has continually challenged us to be creative in how we confront problems, and now is no different. Our rapidly growing use of technology, including telemedicine and teleconsults, will enable us to continue to perform as a closely knit organization where ideas, skills, and expertise are generously shared for the benefit of our patients and our physicians."

Dr. Tsai echoes that thought. "What defines New York Eye and Ear is not a single building or way of thinking," he declares. "Instead, it's our rich history, our steadfast service to the community, and our remarkable faculty (both full-time and voluntary), physicians, trainees, and staff. Those strengths are enduring and will only multiply as we continue to grow our widely recognized brand across the metropolitan area."



# Eye Plaque Radiation Therapy Preserves the Sight of Patients With Invasive Carcinoma

New York Eye and Ear Infirmary of Mount Sinai (NYEE) started its eye radiation therapy program in the early 1990s. Since that time, its ophthalmologists have offered eye- and vision-sparing treatments with great success for more and more complex cases. In two such cases, patients who each had squamous cell carcinoma that grew from the conjunctiva into the eye illustrate the breadth of skills, training, and decision-making required for these delicate procedures.

The first patient was a 56-year-old severe diabetic, with secondary glaucoma and multiple corneal transplants. To make things worse, he was diagnosed with squamous cell carcinoma that had invaded through his corneal transplant wound into his only functioning eye. Here the surgeons were not only challenged by the unusual intraocular invasion, but also by the knowledge that failure of treatment would result in total blindness.

The solution? Sewing a disc-shaped radiation source on the cornea to cover the tumor. “Years ago surgeons would have tried to cut these tumors out of the eye. Then in 1993, we published a study showing that intraocular tumors in the iris and ciliary body could be treated through the cornea with radioactive plaques,” says Paul T. Finger, MD, FACS, Founding Director of the Ocular Oncology Service at NYEE. “This approach has enabled us to avoid large sight-threatening surgeries and preserve both the patient’s eyes and eyesight.”

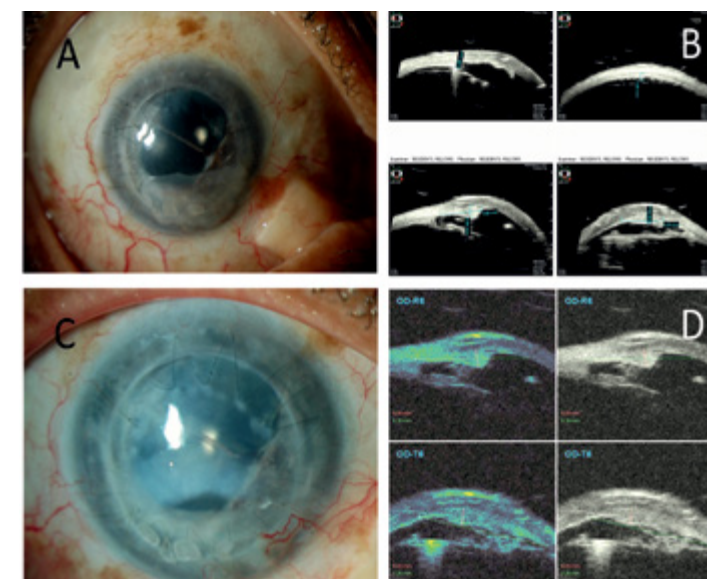
In the case of the monocular patient, Dr. Finger used plaque brachytherapy with palladium-103 radioactive seeds—a low-energy gamma source. The seeds are affixed within a gold, dime-size device placed on the cornea over the area that needed treatment. The gold seed carrier blocks the radiation in every direction except into the eye, directly at the tumor, thus sparing healthy tissues. “The beautiful part of the procedure is that it’s a very localized treatment to just the front part of the eye, precisely where the tumor is situated,” explains Dr. Finger.

After seven days of continuous plaque radiation at a dose of 84.5 Gy, the device was removed from the cornea, leaving

the tumor destroyed. The NYEE surgeons, who included Dr. Finger and Ekaterina Semenova, MD, PhD, then an ophthalmic clinical research fellow, and a radiation oncologist, achieved local tumor control and preservation of the patient’s vision. Specifically, examination with slit-lamp photographic and high-frequency ultrasound imaging at eight years’ follow-up showed a reduction of the tumor to a scar, and mild hazy opacity of the corneal transplant, but only within the targeted zone.

Dr. Semenova has since become the newest member of the Ocular Oncology Service team as an Assistant Professor of Ophthalmology (after completing an ophthalmology oncology fellowship program at Duke University), which also includes Robert D. Stewart, MD, Assistant Professor of Radiation Oncology at the Icahn School of Medicine at Mount Sinai, who supervises dosimetry and plaque construction. Dr. Semenova quickly put her surgical skills and training to work on the latest squamous cell carcinoma case. It involved a 49-year-old woman whose tumor on the surface of the cornea was shown by high-frequency ultrasound to be growing down into the eye from a penetrating keratoplasty (PK) wound. The patient was referred to NYEE where Drs. Finger and Semenova initially reduced the size of the tumor on the ocular surface with chemotherapy eye drops. However, knowing that chemotherapy eye drops are not effective beyond the surface of the eye, Dr. Semenova now faced a critical decision: how to treat the residual invasive tumor.

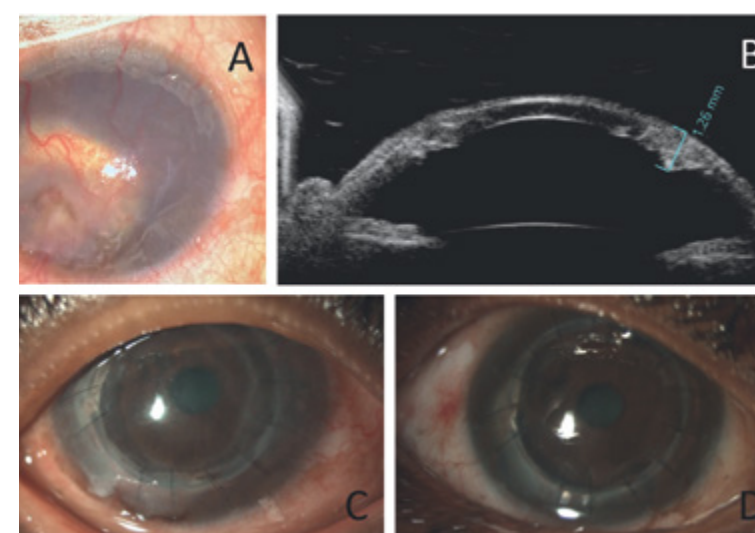
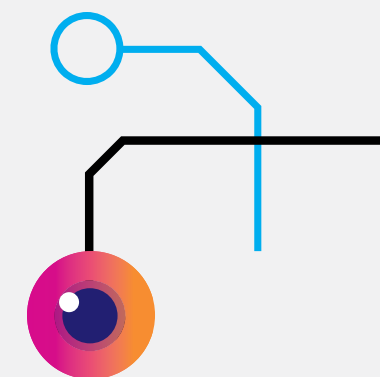
“It became a choice of using radiation to preserve or alternatively to remove the eye to ensure the tumor didn’t return,” she explains. “I decided to go with radiation, and sutured a plaque loaded with radioactive palladium-103 onto the surface of the entire cornea.” The plaque was sutured to the front of the eye and left there for a week to deliver a treatment dose of 70 Gy to the intraocular tumor cells. While longer-term results from the procedure (performed last year) are not yet available, initial findings are extremely favorable. “The patient’s pressure is normal, the eye looks good, and the corneal transplant is clear,” reports Dr. Semenova. “Her vision was 20/50 before and continues after the treatment, supporting our decision to use radiation therapy to spare the eye.”



**Fig. 1: 2014 Patient Case**  
**A:** Squamous carcinoma transplanted cornea with tumor invasion through corneal transplant wound (arrows)  
**B:** Ultrasound imaging showing tumor invasion through corneal transplant wound (arrows)  
**C:** Slit lamp picture showing regression of the cancer and formation of stromal opacity of the corneal transplant within the targeted zone  
**D:** Ultrasound imaging reveals regression of the tumor

“The beautiful part of the procedure is that it’s a very localized treatment on the front part of the eye, precisely where the tumor is situated.”


—Paul T. Finger, MD



**Fig. 2: 2022 Patient Case**  
**A:** Intraoperative picture of the corneal opacity with corneal and conjunctival tumor of the right eye prior to penetrating keratoplasty  
**B:** Ultrasound imaging showing tumor invasion through corneal transplant wound  
**C:** Slit lamp picture showing residual corneal and conjunctival tumor infero-temporally  
**D:** 3 months post plaque radiation therapy with regression of corneal and conjunctival tumor and clear corneal transplant



# A New Industry Partner Is a Milestone for Ophthalmic Robotics



The recent acquisition of ophthalmic robotics company Preceyes, Inc. by industry leader ZEISS Medical is a major win for the Mount Sinai/NYEE Innovations team, which was the lead technology partner in the first clinical robotics venture in ophthalmology. The world's first clinical eye surgical robotic system, and the only one in the United States, was installed at New York Eye and Ear Infirmary of Mount Sinai (NYEE) in the summer of 2020. The backing by one of the largest surgical device manufacturers like ZEISS—a \$14 billion global enterprise—means more depth and breadth of resources and expertise in the advancement of surgical robotics in the field of ophthalmology.

The addition of a global industry partner will enhance the relationship begun several years ago with a generous grant from the RICBAC Foundation to fund the NYEE surgical robotics initiative and further championed through the efforts of Tsontcho (Sean) Ianchulev, MD, MPH, Professor of Ophthalmology at the Icahn School of Medicine at Mount Sinai and Director of Ophthalmic Innovation and Technology at NYEE.

“At the peak of the pandemic, NYEE and Mount Sinai doubled down on microsurgical robotics innovation by serving as the only institutional investor in Preceyes,” says Dr. Ianchulev, a widely known innovator who will serve on the advisory board of Preceyes/ZEISS. “Our new collaboration with a global leader like ZEISS will allow for continued development of the next generation of anterior segment applications. These include angle-based glaucoma surgery with an achievable level of precision through the robot of five microns, compared to 100 microns manually.”

The value of the acquisition is underscored by Erik Lium, PhD, President, Mount Sinai Innovation Partners (MSIP), which has provided critical support for NYEE's surgical robotics program, including institutional investment in the company. “Bringing advanced technology to market that can improve health care and the lives of patients is extremely complex and costly,” says Dr. Lium, who previously represented Mount Sinai on the board of directors of Preceyes. “Having the backing of an innovation leader like ZEISS will provide the levels of expertise and resources needed to allow the microsurgical robotic assistant to become the leader in its field.”

The first robotic module on track for U.S. Food and Drug Administration approval is aimed at retinal microsurgical intervention. Dr. Ianchulev expects clinical trials on that platform to begin over the next 12 months. In addition, he and Gautam Kamthan, MD, Assistant Director of Ophthalmic Innovation and Technology at NYEE,

presented at the American Academy of Ophthalmology conference the first surgical robotic module for anterior segment/glaucoma surgery. That application is the product of a collaboration between NYEE's innovation group and the Preceyes engineering team, with a seed grant from the New York Eye and Ear Infirmary Foundation.

Future plans call for adding instrumentation that would integrate the surgical robot with intraoperative optical coherence tomography, allowing the device to navigate deftly within the microscopic three-dimensional space of the retina layers and vessels, according to Richard Rosen, MD, Distinguished Professor of Ophthalmology at the Icahn School of Medicine at Mount Sinai, Vice Chair of Ophthalmology Research at NYEE, and Chief of the Retina Service at the Mount Sinai Health System, who has been an integral part of the robot's implementation.

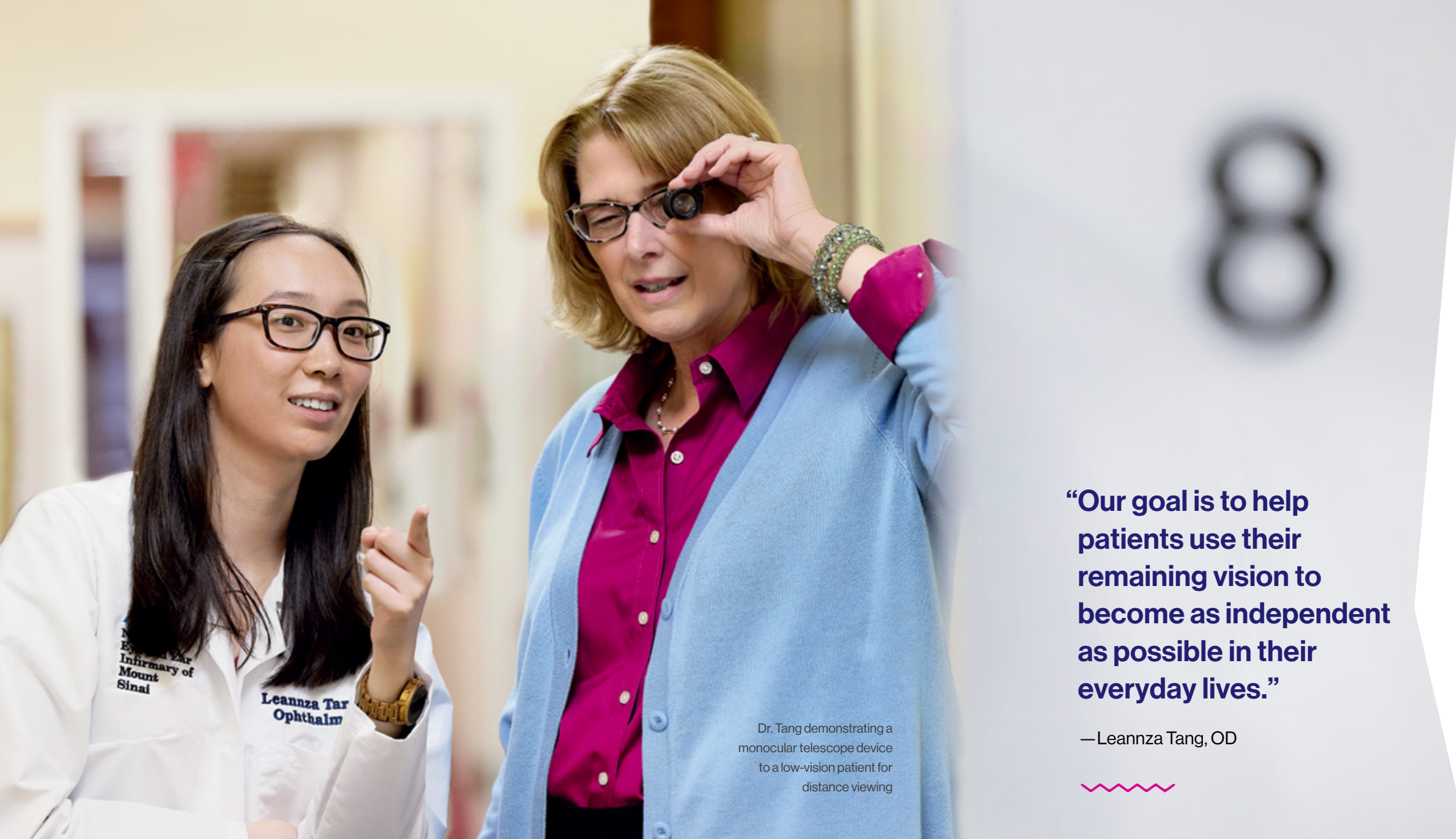“Through the robotic initiative, we're expanding upon our clinical-scientific-industry model for innovation to bring new therapeutic capabilities for the benefit of our patients and the entire field of ophthalmic care,” he notes. “Clearly, the surgical robot is an extension of NYEE's history as a national center of microsurgical excellence in ophthalmology, as well as a launchpad for next-generation image-guided robotic eye surgery.”

*Dr. Ianchulev is a Professor of Ophthalmology and part-time faculty member at NYEE and the Icahn School of Medicine at Mount Sinai. Dr. Ianchulev was an advisor and equity holder with Preceyes prior to the acquisition and leads the NYEE robotics program. He is also the founder, board member, and/or equity owner of multiple life-science companies, including the public company Eyenovia, Inc., and private companies Iantrek, Inc., and Aeye, Inc. As a prominent innovator in the field of ophthalmology, he is the holder of multiple issued and pending patents.*

**“At the peak of the pandemic, New York Eye and Ear and Mount Sinai doubled down on microsurgical robotics innovation by serving as the only institutional investor in Preceyes.”**

—Tsontcho A. Ianchulev, MD, MPH

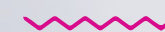



Dr. Tang demonstrating a monocular telescope device to a low-vision patient for distance viewing

**“Our goal is to help patients use their remaining vision to become as independent as possible in their everyday lives.”**

—Leannza Tang, OD



curriculum through lectures and practical experience with clinic patients. Specifically, trainees are introduced to the various low-vision devices available to patients, such as magnifiers, non-optical aids, and assistive technology. The success of this effort is reflected in the increase in referrals by residents to the Low Vision Clinic. By ramping up her communications efforts, Dr. Tang continues to increase low-vision referrals from other ophthalmic specialists at Mount Sinai and eye care providers in the tristate area. She has already expanded her service, splitting time between NYEE’s uptown faculty practice on 102nd Street and its downtown eye clinic and faculty practice on 14th Street. The latter site has also opened an optical shop that offers many low-vision aids to the public.

Low vision is generally characterized as 20/70 or worse acuity in the better-seeing eye, not correctible with standard glasses, contact lenses, medicines, or further surgery. “I like to explain to my patients that I’m more focused on their visual rehabilitation and how they’re functioning day to day,” explains Dr. Tang, who completed her low-vision rehabilitation residency at the State University of New York College of Optometry before joining NYEE. “I want to know if they’re having difficulty reading small print in newspapers and books or seeing things like street signs and bus numbers. Some glaucoma patients, because of their constricted peripheral vision, might have trouble walking around without tripping or have difficulty navigating stairs and curbs.”

Individuals are offered a range of traditional as well as exciting new technology-driven devices and applications. The former includes optical devices like handheld and stand magnifiers, which can enlarge print material. Nonoptical devices may include proper lighting through flexible-arm task lamps, reading stands (which bring written materials closer to the eye), absorptive sunglasses (which filter out bothersome glare), and reading or writing guides (to help individuals keep their place while reading or signing their name, for example).

Dr. Tang is also prepared to recommend the latest generation of smartphone apps being rolled out commercially for visually impaired people. For example, “text-to-speech” applications and screen readers can read text such as emails, web pages, and books aloud. Other smartphone apps can identify colors and currency, describe people and objects, and much more.

Beyond visual aids, the Low Vision Clinic is prepared to refer patients to experienced organizations in the city for mobility and functional training. “In cases where it doesn’t make sense for us to recreate what already exists, we connect them with organizations like Lighthouse Guild and VISIONS,” explains Dr. Sidoti. “We in effect broker these arrangements so that our patients are assured of getting specialized services best tailored to their needs.”

# Helping Low-Vision Patients Lead Independent Lives

For all their hard work to preserve and restore eyesight, ophthalmologists often reach the limits of what they can accomplish with standard treatment. As a result, countless patients with disorders like glaucoma, macular degeneration, and diabetic retinopathy must cope with permanent low vision—and few insights on how to improve their quality of life.

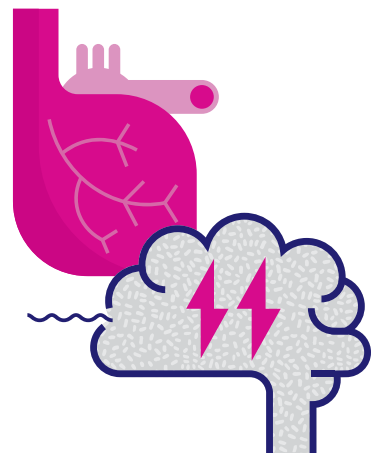
“Traditionally, physicians have been poorly trained in how to manage low vision in patients who have already been treated with medicine or surgery,” says Paul A. Sidoti, MD, Chair, Ophthalmology, New York Eye and Ear Infirmary of Mount Sinai (NYEE). “Since a large percentage of our patients come to us with complex eye problems, it’s important for our ophthalmologists to know what in-house resources are available, and when to plug low-vision patients into outside services like Lighthouse Guild and VISIONS.”

The centerpiece of that initiative at NYEE is the Low Vision Clinic. In February 2021, Leannza Tang, OD, became its first full-time director with the help of a grant from the Lavelle Fund for the Blind. She has been working tirelessly since, not only to offer assistance to visually impaired patients, but also to spread the word about the program to ophthalmologists, optometrists, and family practice physicians throughout the Mount Sinai Health System. “Low-vision rehabilitation is unfortunately a very underutilized service,” emphasizes Dr. Tang, “and much of that is due to the lack of awareness by both professionals and patients. Our goal is to help patients use their remaining vision to become as independent as possible in their everyday lives.”

NYEE ophthalmology residents are vital players in that campaign. Low-vision training is now embedded into their



# Looking for Macular Degeneration In All the Right Places



For at least 30 years, scientists have attempted to show an association between age-related macular degeneration (AMD), cardiovascular disease (CVD), and stroke, but concrete results have proven elusive. A new study led by a team from New York Eye and Ear Infirmary of Mount Sinai (NYEE) suggests the reason why: past investigations were focused on only a partial picture of the disease pathology.

According to the latest study, published in the July 2022 issue of *RETINA*, researchers detected, through retinal imaging of patients, two distinct disease pathways leading to advanced age-related macular degeneration. One is soft drusen beneath the retinal pigment epithelium (RPE), and the other is subretinal drusenoid deposits (SDDs) above the RPE. Each of these lipid-bearing deposits is tied to different sets of risk factors (including serum and genetic), but in only one pathway—SDDs—do they include cardiovascular disease and stroke. These findings could have significant public health implications in screening for macular degeneration, the leading cause of blindness, and cardiac disease and stroke, the leading causes of death in the developed world.

“Scientists couldn’t find the link between AMD and CVD and stroke in the past because they weren’t looking at the right population with AMD,” explains lead author R. Theodore Smith, MD, PhD, Professor of Ophthalmology, Icahn School of Medicine at Mount Sinai, and Director of Biomolecular Retinal Imaging, NYEE. “We learned that if OCT (optical coherence tomography) shows a patient has subretinal drusenoid deposits—which occur in about half of AMD cases—they’re at a much higher risk for life-threatening cardiovascular disease and stroke. At the same time, if cardiac imaging shows an irregularity, the patient is a much stronger candidate for AMD and should also be screened for that condition.”

Dr. Smith and his team believe the connective thread between AMD and CVD is vascular. Poor ocular circulation of blood not only results in subretinal drusenoid deposits but can also serve as an important marker for systemic vascular disease impacting the heart. “We now have a way to screen or study patients who have either macular degeneration

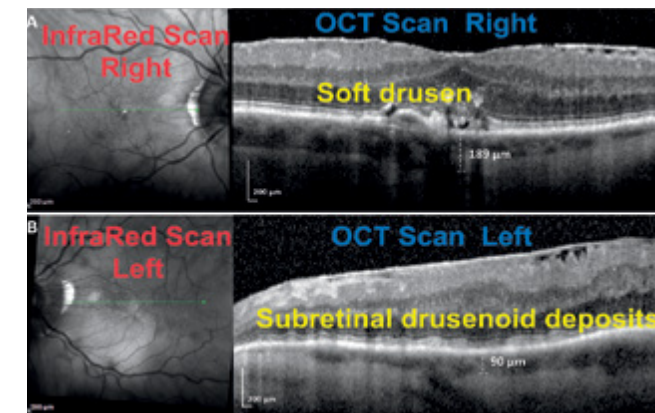
or significant cardiac or neurovascular disease and find out who might also be harboring the other,” points out Dr. Smith. “This could provide a critical new diagnostic tool for identifying the millions of people who walk around not knowing they have a disorder that could be life-threatening or sight-threatening.”

To that end, Dr. Smith is working closely with Jagat Narula, MD, PhD, Philip J. and Harriet L. Goodhart Professor of Medicine and Director of the Cardiovascular Imaging Program at the Icahn School of Medicine at Mount Sinai, on collaborative research that spans both of their imaging fields. Specifically, NYEE is building on the cutting-edge diagnostic work of Dr. Narula and other Mount Sinai scientists using CT scanning and tracer isotopes to detect coronary artery disease. NYEE, for its part, employs gold-standard OCT scanning and even more advanced spectral domain OCT to detect subretinal drusenoid deposits above the retinal pigmented epithelium. A combination of these modalities will help to drive ongoing research designed to correlate cardiac disease and stroke with age-related macular degeneration.

Another player in that collaborative effort will be the Blavatnik Family Women’s Health Research Institute at Mount Sinai. Recognizing that coronary artery disease is an alarmingly neglected area of public health, the Institute is helping to develop research that will target women with high-risk vascular conditions that have been understudied in the past.

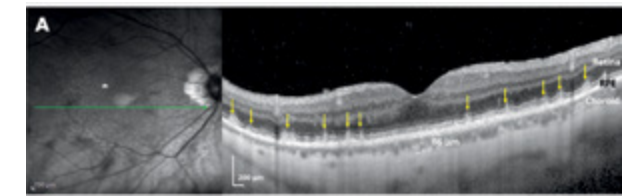

The latest discovery by NYEE and Mount Sinai researchers of dual AMD pathways will help to accelerate that study and others into the pathogenic mechanism of AMD. “By separating AMD into two different diseases, we stand a much better chance of figuring out what’s occurring at the cellular level of each,” observes Dr. Smith. “And that could potentially lead to new medications or treatments to improve the circulation or blood supply to the vessels of the eye, for example. Clearly, being able to apply our research on a population scale to vascular disease screening and treatment could benefit countless numbers of people worldwide.”

**Subretinal drusenoid deposits (SDDs)** are driven by carotid stenosis, myocardial failure, and cardiac valvular dysfunction. Figures 1, 2, 3 illustrate three major categories of vascular disease causing the SDD form of age-related macular degeneration (AMD), not soft drusen. Infrared reflectance scans are paired with corresponding optical coherence tomography (OCT) scans in standard format for retinal OCTs.

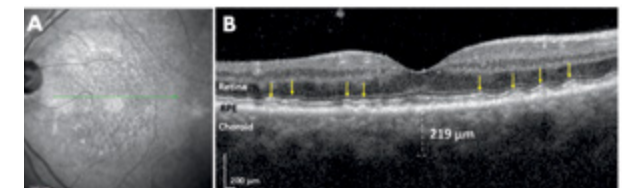


**Fig. 1: Left-Sided Stroke and Internal Carotid Artery (ICA) Stenosis**

**A: Right Eye**  
**Infrared scan:** Bright drusen centrally. **Green line:** Location of OCT scan. **OCT scan:** Confluent soft drusen centrally, under and elevating the bright retinal pigment epithelial (RPE) band. No SDD. Choroidal thickness, 189 microns.  
**B: Left Eye**  
**Infrared scan:** Multiple homogeneous dark lesions of SDD. **Green line:** Location of OCT scan. **OCT scan:** Smooth waves of SDD over the bright RPE and under the retina (**stage 2**). Choroidal thickness, 90 microns. SDDs and choroidal thinning are present only in the left eye, where ICA stenosis compromises ophthalmic artery and choroidal perfusion. The uncompromised right eye has no SDD and normal choroidal thickness, an experiment in nature showing **that the carotid perfusion deficit precisely determines the SDDs.**



**Fig. 2: Myocardial Infarction (MI) Right Eye**  
**Infrared scan:** Multiple homogeneous dark lesions of SDD  
**Green line:** Location of OCT scan. **OCT scan:** Multiple SDD (yellow arrows) with a conical appearance above the RPE penetrating the overlying retina (**stage 3**). Choroidal thickness, 86 microns. Choroidal thinning is also due to the myopia, but myopia is not a cause of SDD. **The SDD are caused by the poor systemic perfusion in the setting of MI.** Left eye was similar.



**Fig. 3: Severe Aortic Stenosis Left Eye**  
**Infrared scan:** Multiple homogeneous dark lesions of SDD. **Green line:** Location of OCT scan. **OCT scan:** Multiple SDD (yellow arrows) in several smooth, wave-like series. The measured choroidal thickness of 219 microns corrected for hyperopic refractive error is -169 microns, more typical for SDD. The right eye had been lost to glaucoma and vascular disease. **Aortic stenosis is an example of a cardiovascular disease unrelated to atherosclerosis, but compromising cardiac output and ophthalmic perfusion, hence causing SDDs.**



# Unraveling the Wound-Healing Magic of the Corneal Epithelium

The corneal epithelium plays an indispensable though little-understood role in marshaling armies of healing stem cells from the limbal rim to the protective surface of the eye in the event of an injury. For the first time, a team of scientists from the Icahn School of Medicine at Mount Sinai, Wilmer Eye Institute, and Johns Hopkins University School of Medicine has shed valuable light on that wound-healing process and the vital contribution of the c-Myc gene, with major implications for future research and treatment of a blinding disease known as limbal stem cell deficiency (LSCD). Their study was published in the February 2022 issue of *Investigative Ophthalmology & Visual Science*.

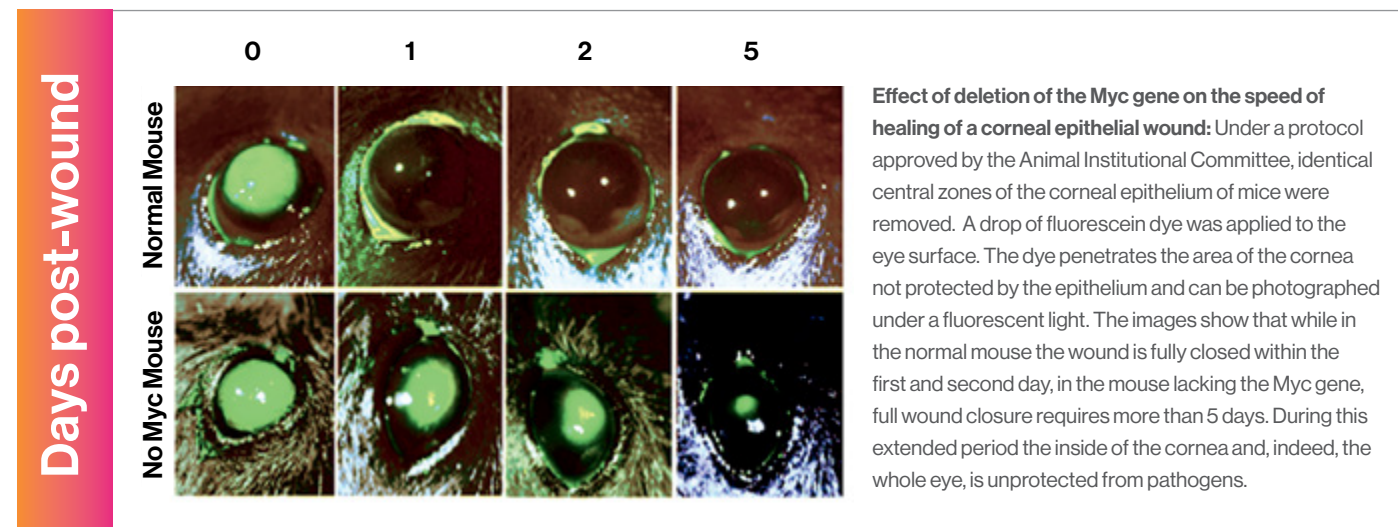
“The c-Myc gene serves as the master regulator of cellular metabolism and proliferation through the modification of gene expression patterns,” explains corresponding author J. Mario Wolosin, PhD, FARVO, Professor of Ophthalmology, Black Family Stem Cell Institute, Icahn School of Medicine at Mount Sinai. “Specifically, we found that c-Myc is a critical mediator of the proliferative response that limbal stem cells mount when faced with the need to rapidly repopulate the ocular surface if a physical, chemical, or other type of injury occurs.”

Indeed, the self-renewing properties of the corneal epithelium depend on the migration of stem cells, which are housed in the narrow outer rim of the cornea known as the corneal limbus. Normally, cells constantly exfoliate

at the ocular surface of the eye and are replaced by new cells derived from the corneal limbus. If a large part of the epithelium is lost through injury, however, corneal epithelial cell production is dramatically accelerated to cover the denuded area and thereby prevent infection and pathogenic infiltration of the eye.

When the corneal rim itself is damaged or weakened by a physical or chemical insult or by a fulminant inflammatory allergic reaction such as Stevens-Johnson syndrome, the sudden loss of stem cells results in limbal stem cell deficiency, a potentially blinding condition caused by invasion of the cornea by the surrounding conjunctival epithelium and subsequent swelling, inflammation, and infection. The only permanent treatment is to extract healthy limbal cells through a biopsy from the limbus of an immune-compatible donor, expand them in culture, and apply them as a high-density “sheet” over the damaged eye.

“The identification of c-Myc as a master regulator opens the door to improving the generation of transplantable limbal stem cell sheets to treat limbal stem cell deficiency and restore the damaged corneal surface,” says Dr. Wolosin. “This type of advance could not only help save the sight of many LSCD patients but open the door to further research around the cellular interactions of c-Myc with the corneal epithelium, and to other innovative wound-healing treatments.”



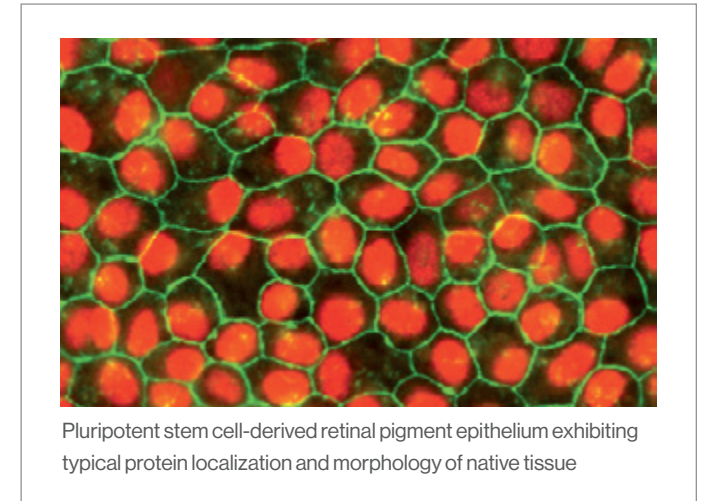
# Researchers Target a Major Hurdle For Retinal Stem Cell Replacement

Stem cell replacement therapy promises to usher in a new era in ophthalmic medicine, and nowhere are the hopes higher than with age-related macular degeneration (AMD), the leading cause of blindness, which affects more than 200 thousand individuals worldwide. A number of human trials using induced pluripotent stem cells (iPSC) to replace lost retinal pigment epithelium (RPE) have shown encouraging results in restoring some vision, but they come with a complication: the production of epiretinal membranes.

A team of researchers at the Mount Sinai/New York Eye and Ear (NYEE) Eye and Vision Research Institute has discovered a potential way around this adverse event, which has impeded progress in the field of iPSC-RPE cell replacement. As reported in the August 2022 issue of *Frontiers in Cell and Developmental Biology*, the approach provides for inhibition of the p38 signaling pathway, minimizing the likelihood of epiretinal membrane formation as well as proliferative vitreoretinopathy, which is fueled by inflammation from the transplant surgery.

“We’ve found a way to improve cell stability with RPE transplantation that may reduce the occurrence of adverse events observed in the clinic,” says senior author Timothy Blenkinsop, PhD, Associate Professor of Ophthalmology, and Cell, Developmental, and Regenerative Biology, Icahn School of Medicine at Mount Sinai. “Our study could lead to new protocols for retinal transplantation using iPSCs, which, because of their self-renewal capability, are a highly promising source to generate unlimited RPE for cell therapy.”

Postulating that the source of epiretinal membrane formation could be incomplete cell maturation, Dr. Blenkinsop and his team conducted a comparison of gene expression profiles between iPSC-RPE, adult primary RPE taken from the human eye, and RPE from the immortalized ARPE-19 cell



line, a popular source for studying RPE biology. They found that iPSC and adult primary sources were comparable in their ability to express normal RPE genes, and did so at a higher level than the ARPE-19 cell line. What’s more, iPSC-RPE expressed networks involved in early eye development and muscle contraction. The downside, however, is the finding by researchers that iPSC-RPE exhibits an epigenetic plasticity, meaning a tendency to change its physiology and structural properties when placed in an inflammatory environment, such as stem cell transplantation surgery.

“We developed a model for our study that mimicked the inflammatory environment that induces proliferative vitreoretinopathy, and showed that iPSC-RPE changes its physiology to become less RPE-like and more muscle-like,” explains Dr. Blenkinsop. “Just as importantly, we discovered that p38 inhibition can repress production of these contractile membranes, potentially minimizing adverse events. Reducing the risk of epiretinal membrane formation would represent a major step forward for RPE cell replacement therapy.”

**“We’ve found a way to improve cell stability with RPE transplantation, which may reduce the occurrence of adverse events observed in the clinic.”**

— Timothy Blenkinsop, PhD



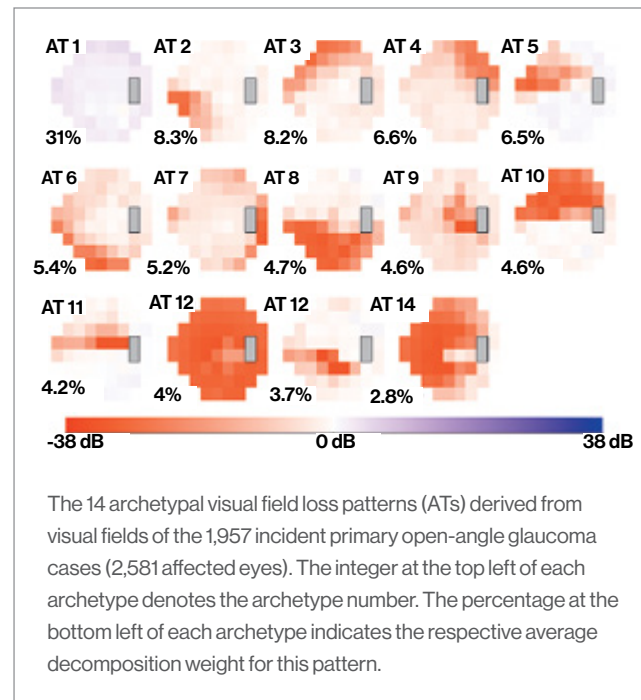
# A New Study Finds Blacks Have More Advanced Visual Field Loss At First Diagnosis of Glaucoma

Using a technique called archetype analysis to evaluate patterns of visual field loss, Louis R. Pasquale, MD, at New York Eye and Ear Infirmary of Mount Sinai (NYEE), in conjunction with collaborators at Brigham and Women's Hospital and Massachusetts Eye and Ear, uncovered critical new information regarding primary open-angle glaucoma (POAG) among U.S. health professionals. Applying archetype analysis, a form of artificial intelligence (AI), to new-onset visual field loss associated with POAG revealed 14 visual field loss patterns ranging from mild peripheral loss to advanced damage across the entire field of vision. The results, published in the July 2022 issue of *Translational Vision Science and Technology*, showed that Blacks were at a significantly higher risk of POAG with early advanced functional damage compared to non-Hispanic whites.

“With this work, we essentially decompose the visual fields from newly diagnosed primary open-angle glaucoma to help disentangle disease pathogenesis,” says Dr. Pasquale, Deputy Chair for Research and Director, Mount Sinai/NYEE Eye and Vision Research Institute, Icahn School of Medicine at Mount Sinai. “Our data showed that being of African heritage is the No. 1 risk factor for presenting with more advanced forms of vision loss, providing insight into why African ancestry is a risk factor for glaucoma blindness.”

POAG is a multifactorial optic neuropathy that manifests as distinct visual field loss patterns localizing to the nerve fiber layer. This collaborative research team applied archetype analysis through an AI algorithm to three population-based cohorts of nurses and health professionals to identify visual field loss patterns in Blacks, Asians, and Hispanic whites compared to non-Hispanic whites. In addition to early-onset visual field imaging, the study's data set was enriched by demographic, genetic, medical, and lifestyle information; the hope is that further research will reveal unique disease determinants for the different patterns of visual loss encountered in glaucoma.

“Our study has tremendous implications for glaucoma screening of Blacks, who we know as a population are least likely to have regular eye exams in the United States,” notes Dr. Pasquale. “Screening earlier in life could significantly increase their chances of detecting a potential glaucoma problem before it reaches one of the advanced patterns shown in our research.”



**“Our data showed that being of African heritage is the No. 1 risk factor for presenting with more advanced forms of vision loss, providing insight into why African ancestry is a risk factor for glaucoma blindness.”**

—Louis R. Pasquale, MD





# Uncovering Glaucoma's Vascular Link in People of African Descent

Alon Harris, MS, PhD, FARVO, has committed 30 years of research to chipping away at the notion that intraocular pressure (IOP) is the predominant risk factor for open-angle glaucoma (OAG), particularly in people of African descent. Through his internationally acclaimed work, the Professor of Ophthalmology and Vice Chair of International Research at the Icahn School of Medicine at Mount Sinai has demonstrated that vascular abnormalities can result in reduced blood flow through the retrobulbar vessels and within the retina, which, in turn, are predictive of worse glaucoma progression in people of African descent.

With the help of funding from the National Institutes of Health (NIH) and the National Science Foundation, Dr. Harris and his team are taking that research to the next level by integrating artificial intelligence (AI) and mathematical modeling with clinical and research data to better understand the role that race—as well as other risk factors, such as structural properties of the eye, ocular blood flow, and systemic conditions—plays as a risk modifier and contributor to OAG pathophysiology. For this purpose, Dr. Harris has assembled a multidisciplinary research team comprising glaucoma specialists, physiologists, mathematicians, and bioengineers.

“The only risk factor that has been approved by regulatory authorities for treating glaucoma is high intraocular pressure,” says Dr. Harris. “But our research over the years has shown that maintaining normal blood supply to the eye can help to prevent or curb steep glaucoma progression and ensure better visual outcomes by preserving the optic nerve structures. These include the ganglion cells, nerve fibers, and optic nerve. Future treatments may target vascular tissues if these findings are confirmed in larger longitudinal studies.”

Glaucoma is the leading cause of irreversible blindness in people of African descent. Specifically, this population experiences a threefold greater OAG burden compared to people of European descent, with earlier onset and faster disease progression. Not coincidentally, Dr. Harris points out that people of African descent tend to have more systemic vascular disease, including considerably higher rates of cardiovascular disease, diabetes, obesity, smoking, and sedentary lifestyle.

Dr. Harris presented some of the first findings on vascular health differences in African Americans in the 1990s. That research helped to spin off other studies that showed these disparities may include lower vascularity and perfusion of the retina, as well as lower blood flow supplying ocular tissues, and disturbances in retinal oxygen metabolism. And in a landmark population-based study conducted in Thessaloniki, Greece, Dr. Harris, as Co-Principal Investigator, found that low diastolic ocular perfusion pressure—calculated as systemic blood pressure minus intraocular pressure—may be associated with increased risk for glaucoma, particularly in patients treated with antihypertensive medications.

Dr. Harris sees mathematical modeling and AI as essential strategies to build on these earlier results. “To understand the pathophysiology of glaucoma and identify modifiable risk factors beyond IOP, we need to develop a new generation of models that are able to describe the coupling of systems like the biomechanics of ocular tissues, the hemodynamics of ocular blood flow, and the functionality of retinal ganglion cells,” he explains. Modeling and AI in conjunction with clinical and research data can serve as a “virtual lab,” he adds, where risk factors can be isolated and assessed independently of each other, leading to the design of further clinical studies towards individualized medicine.

To that end, Dr. Harris cites the considerable resources he has been able to tap into since moving his lab to the Department of Ophthalmology at New York Eye and Ear Infirmary of Mount Sinai two years ago from Indiana University School of Medicine. As he puts it, “The access to advanced imaging like OCTA coupled with incredibly skilled glaucoma specialists and a wide variety of patients and ethnicities have provided a unique platform to unravel the many questions around glaucoma that remain unanswered.”

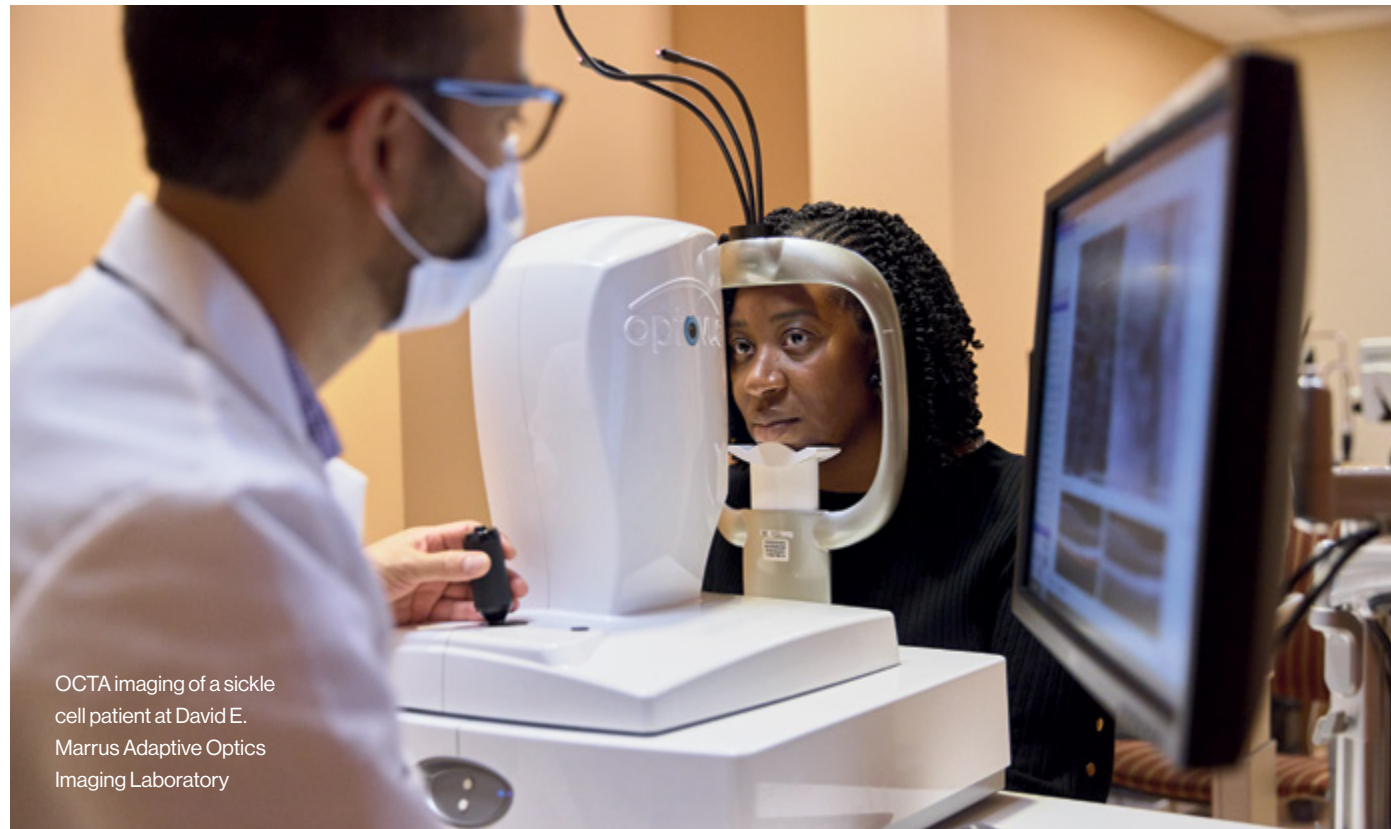With Dr. Harris's findings published in more than 380 peer-reviewed manuscripts and 22 books, it has been gratifying to see recognition for his work not only from his peers but also from the NIH. To date, his study of glaucoma disparity among people of African descent, stemming from retinal and retrobulbar vascular impairments, has received \$3,242,699 in federal support, with a new NIH RO1 grant of \$1.2 million awarded in 2022.



Alon Harris, MS, PhD, FARVO, at the World Trade Center Oculus



# New Imaging Shows First-Time Evidence of Vaso-Occlusion Dynamics in Sickle Cell Disease



OCTA imaging of a sickle cell patient at David E. Marrus Adaptive Optics Imaging Laboratory

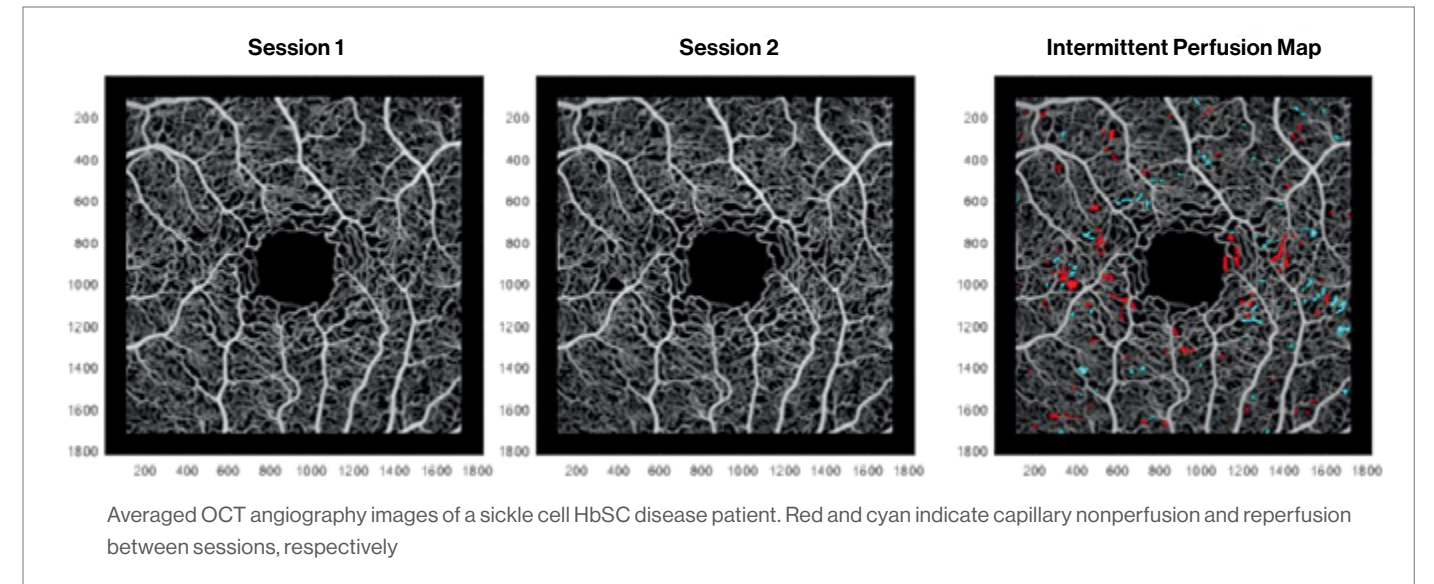
Using breakthrough approaches to sequential imaging of retinal blood flow, New York Eye and Ear Infirmary of Mount Sinai (NYEE) has united the worlds of ophthalmology and hematology in a way that promises to yield significant benefits for more than 100,000 Americans, most of them of African descent, who suffer from sickle cell disease.

In a new study published in the July 2022 issue of *Ophthalmology Science*, researchers reported the use of dynamic optical coherence tomography angiography (OCTA) coupled with specially processed adaptive optics scanning light ophthalmoscopy (AOSLO) to reveal cellular phenomena of sickle cell capillary blood flow in extraordinary detail, opening the door to earlier diagnosis and individualized treatment.

The synergy of these two imaging modalities allowed the team from NYEE and the Department of Medicine at

the Icahn School of Medicine at Mount Sinai to reveal the microscopic details of retinal vaso-occlusion dynamics in patients with sickle cell disease, enabling clinicians to evaluate for each individual the effectiveness of a new wave of therapeutics that have recently become available. That evidence includes intermittent blood flow within capillaries, which open and close momentarily—an early sign of impending vaso-occlusion, which can result in blindness if blood flow is completely shut off. Significantly, OCTA and AOSLO were shown by researchers to be sensitive enough to detect improved retinal perfusion in a sickle cell patient two months following initiation of oral hydroxyurea therapy.

“Despite its clinical advantages, OCTA is still limited in its ability to resolve the details of cellular flow and vessel wall features due to the optical aberrations of the eye,” explains senior author Toco Y. P. Chui, PhD, Director of the David E. Marrus Adaptive Optics Imaging Laboratory and creator of



Averaged OCT angiography images of a sickle cell HbSC disease patient. Red and cyan indicate capillary nonperfusion and reperfusion between sessions, respectively

the software algorithm that allowed for the marriage of the two imaging platforms. “AOSLO compensates for these limitations through its ability to resolve retinal features such as red blood cells and vascular mural cells at a cellular level *in vivo*. For the first time, we’re able to watch sickle red blood cells flow through capillaries and visualize the mechanisms of vaso-occlusion.”

These discoveries are particularly exciting to Jeffrey Glassberg, MD, MA, a co-author of the study and Director of the Mount Sinai Comprehensive Sickle Cell Program, which treats hundreds of sickle cell patients at The Mount Sinai Hospital. “Our research is not only about identifying retinal disease, but more broadly about how sickle cells clump together in tiny blood vessels and can occlude blood flow,” he says. “The retina is really a disease-sensitive capillary bed that serves as a very sensitive proxy for the microvasculature status of other parts of the body, including the brain and kidneys.”

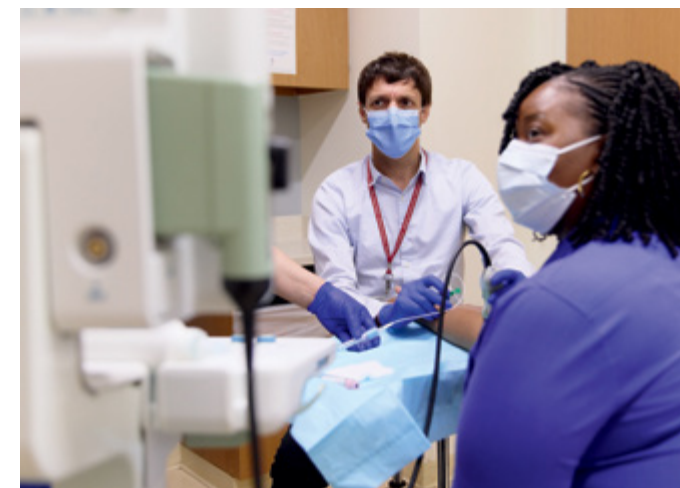A major finding of this joint research, according to Dr. Glassberg, is that sickle cell disease is not always caused by red blood cells that are distorted into sickle shapes and stick to one another, but sometimes by fragments of cellular debris, which monocytes and macrophages are unable to scavenge and eliminate as part of their normal duties. “The discovery that cellular debris can completely

overwhelm the blood circulatory system and impact the level of vaso-occlusion is completely new to the field of sickle cell disease,” Dr. Glassberg notes.

Building on the success of its imaging study, the NYEE/ Mount Sinai team recently launched a new clinical investigation backed by a \$4 million grant awarded by the National Institutes of Health for the next five years. That study plans to enroll and carefully track 200 patients to determine the effectiveness of the recently developed intermittent perfusion index—an algorithm-driven measure of what percentage of blood vessels in the retina are transiently blocked over the course of an hour, based on repeat or sequential imaging during that timeframe. By contrast, repeat scans of individuals without sickle cell retinopathy show continuous blood flow with few if any interruptions.

“The algorithm that Dr. Chui developed allows us to actually see how effective new treatments for sickle cell disease

are for individual patients,” says Richard B. Rosen, MD, Chief of the Retina Service at Mount Sinai Health System and Vice Chair and Director of Ophthalmology Research at NYEE. “Our new study is an important step toward integrating this powerful imaging technology into clinical practice. It moves us closer to individualized medicine and could potentially help determine how new sickle cell drugs get approved.”



Dr. Glassberg, MD drawing blood for a workup to diagnose sickle cell disease



# Two Powerful Imaging Tools Make Their Debut in the United States

Technology continues to hold center stage at New York Eye and Ear Infirmary of Mount Sinai (NYEE), underscored by the recent arrival of two cutting-edge imaging devices: a tear film analyzer and an optical coherence tomography (OCT) Doppler.

“Both devices are examples of what keeps us in the forefront of ophthalmic research,” says Paul A. Sidoti, MD, Chair of Ophthalmology, NYEE. “They are highly sophisticated research and clinical tools that will generate important new information to help us better understand disease processes and thus more accurately diagnose patients and assess the impact of their treatments.”

## The Tear Film Analyzer

It's hard to overstate the importance of the tear film: the first ocular system through which light must pass and the eye's first encounter with the ambient environment. Yet deciphering the complexity of its three layers (lipid, aqueous, and mucoid) to determine the best type and duration of treatment for disturbances that afflict the tear film—like dry eye and ocular surface disease—has always been imprecise.

That's about to change as NYEE becomes the first clinical site in the United States with a tear film analyzer. “This device will allow us to image, separate, and quantify the thickness of each component layer of the tear film,” explains Masako Chen, MD, Assistant Professor of Ophthalmology, Icahn School of Medicine at Mount Sinai. “Having quantifiable measurements of the tear film will allow us to track patients over time and see how they respond to different therapies. It could have a significant impact on our approach to dry eye and ocular surface disease.”

Initially, the tear film analyzer will play a critical research role, enabling Dr. Chen to study a variety of dry eye and ocular surface pathologies from samples she has collected from her patients. “Observing normal versus abnormal conditions will give a lot of comparative data, which eventually could be used to tailor our therapies to patients,” notes Dr. Chen, who is both a scientist and a clinician specializing in cornea and ocular surface diseases.

“The tear film involves all aspects of ophthalmology, which is why we were determined to bring it here for use by all

our clinical departments,” says Richard B. Rosen, MD, Vice Chair and Director of Ophthalmology Research at NYEE, who initially approached Advanced Optical Technologies, Ltd. (AdOM), the small Israeli company that developed the device. “It will change how we treat patients with dry eye especially, because by measuring very fine changes, the tear film analyzer will give us quantitative and objective feedback on the effectiveness of all of our ocular treatments.”

## OCT Doppler

OCT Doppler imaging was first demonstrated 25 years ago, but, thanks to recent innovations and algorithms, has become a more versatile technology with the potential to significantly change glaucoma research and patient treatment. NYEE has been an important part of that development, working closely with Topcon, a well-known developer of ocular imaging devices, to bring OCT Doppler into the clinical space by allowing for high-resolution visualization of blood flow through tiny vessels and the mapping of vascularization networks in humans.

“We've known that blood flow likely plays an important role in the development of glaucoma, but for the first time, OCT Doppler will allow us to take a more in-depth look through our research at the velocity and amount of blood flow to determine if any changes to these metrics occur before we actually see structural damage to the eye from glaucoma,” says Tak Yee Tania Tai, MD, Associate Professor of Ophthalmology at Icahn Mount Sinai, who specializes in glaucoma research and patient management. “This is an exciting development because it could potentially lead to early diagnosis and treatment of a disease that robs so many people of their sight.”

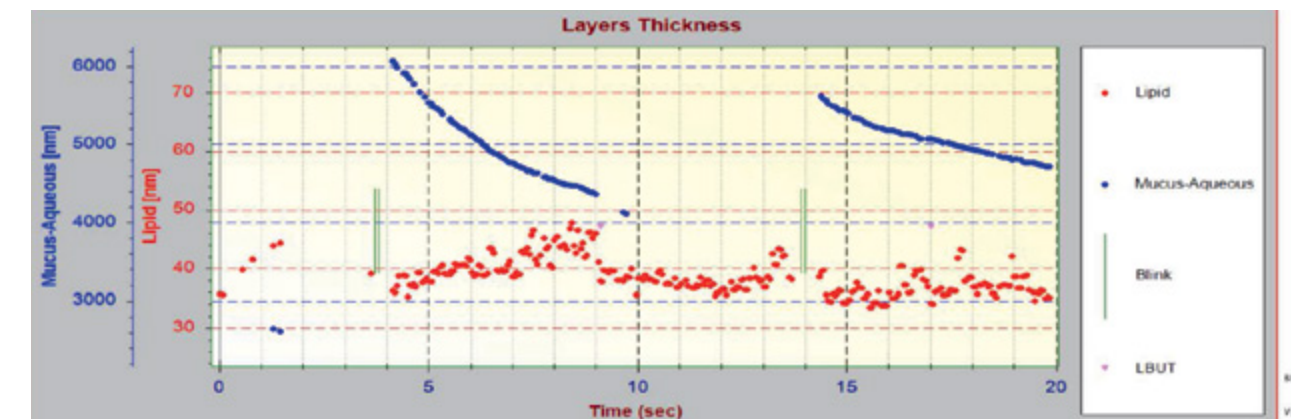
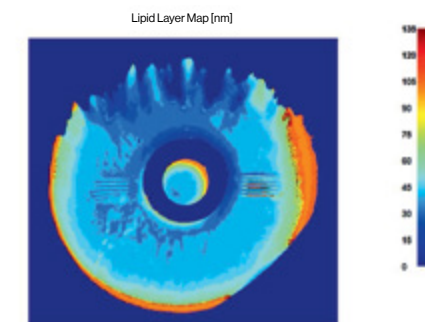
Housed within the Shelley and Steven Einhorn Clinical Research Center at NYEE, the OCT Doppler is expected to shed valuable new light on the recovery dynamics of retinal vein occlusion, measuring how blood flow is reestablished to normal levels following a vascular blockage in the retina, and the impact of blood flow variations in many diseases other than glaucoma, including diabetic retinopathy, macular degeneration, and central serous retinopathy.



Masako Chen, MD

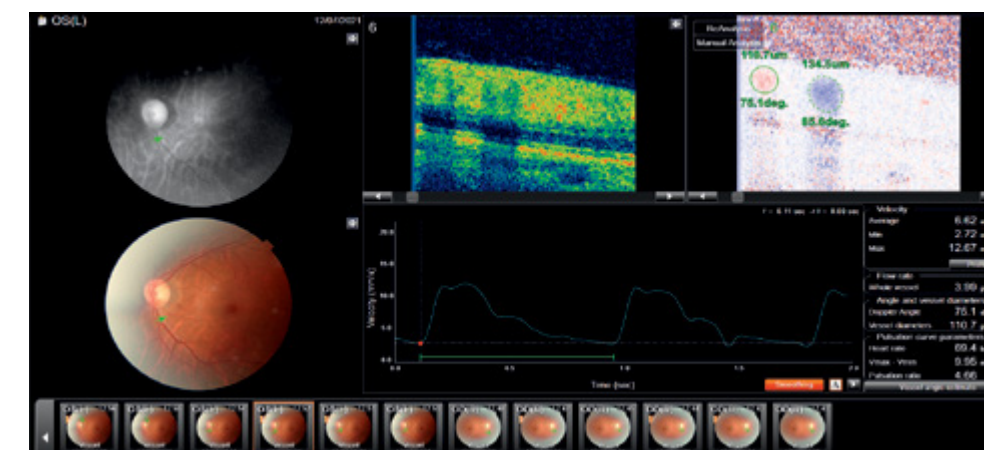
## Tear Film Analyzer

Patient Name / ID	Eye
Age / Gender	Date / Time
TI operator	
Test Duration (sec)	20.042 > 6.0
Measurement	Signal Score (%) > 0.0273
Quality	Position Score < 21
Parameters	Data Continuity (sec) > 2.5
MALT	Mucus-Aqueous Layer Thickness 4548.7 nm
MALTR	Mucus-Aqueous Thinning Rate -460.000 nm/sec
LLT	Lipid Layer Thickness 38.8 nm
LBUT	Lipid Break-Up Time 4.140 sec
IBI	Inter-Blink Interval 10.28 sec
LMU	Lipid Map Uniformity 9.6 squared nm



Example of a report from the Tear Film Analyzer showing thickness of the tear film inner layers (muco-aqueous layer and lipid layer) using spectral interference technology

## OCT Doppler

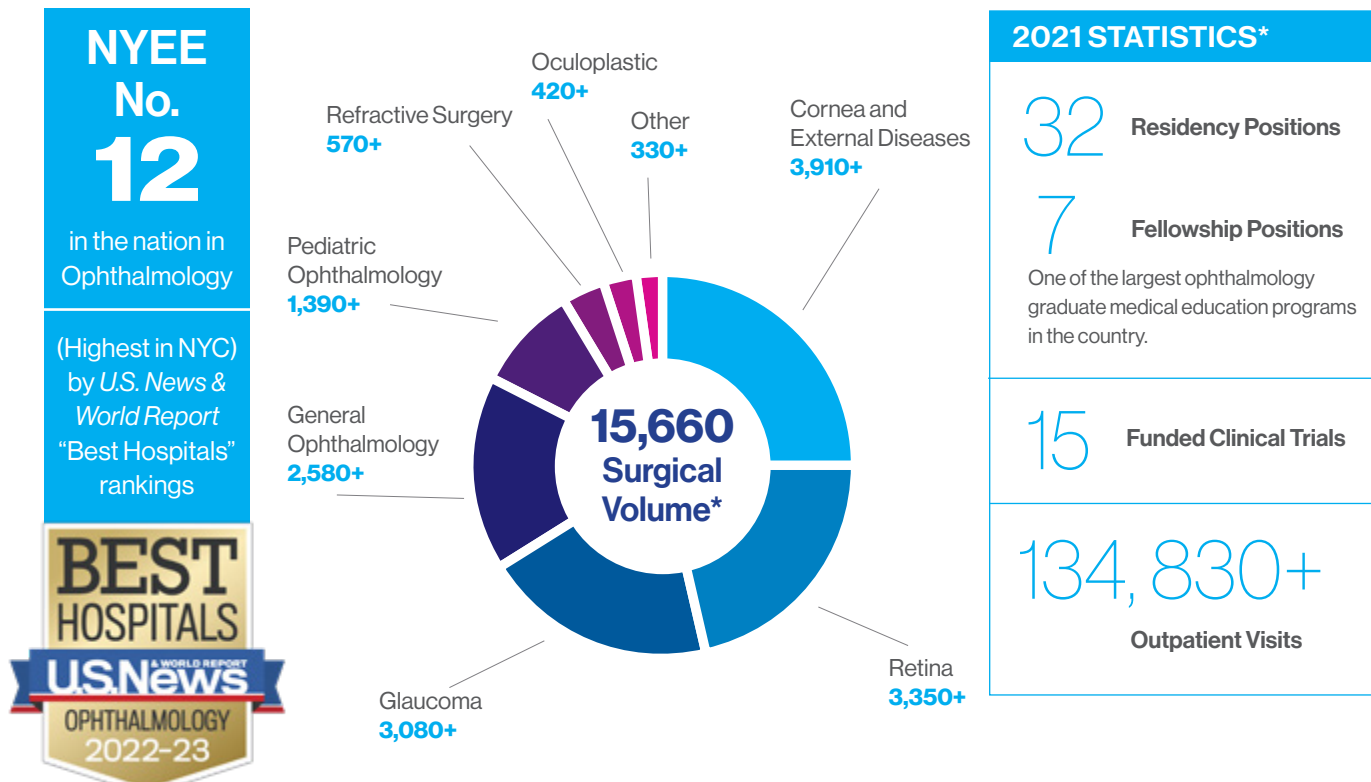


Tania Tai, MD

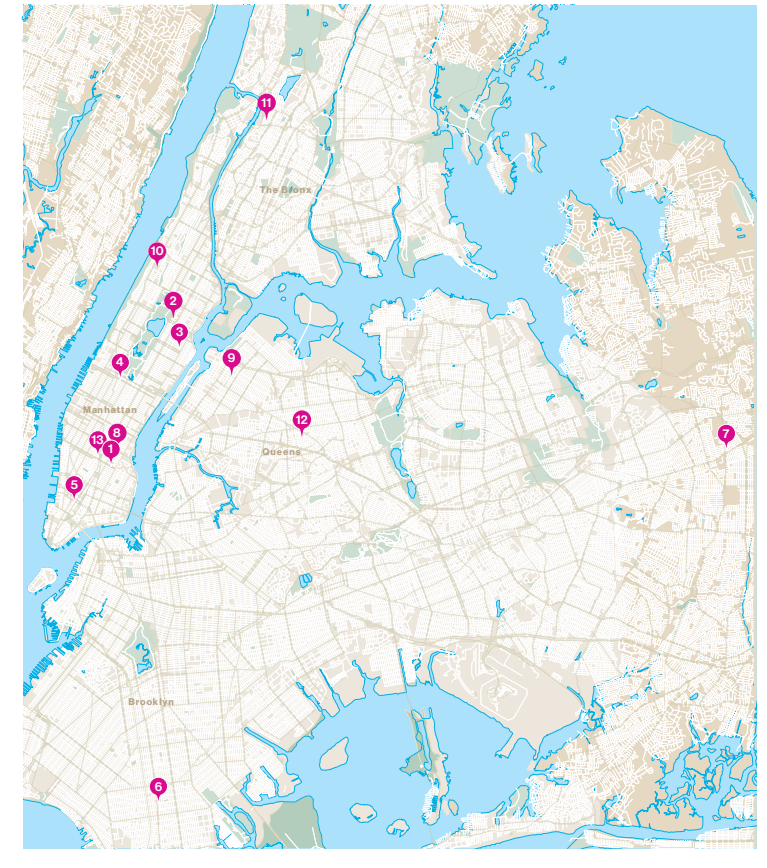
Measurement of retinal blood flow biomarkers in a healthy subject using OCT Doppler: **Upper Right:** Cross-sectional image with the artery highlighted in red and the vein highlighted in blue; **Bottom Left:** Color fundus photo indicating selected blood vessel (green arrow); **Bottom Right:** Blood vessel analysis of the selected artery with average velocity, blood flow rate of the selected artery, vessel diameter, heart rate, and other parameters outlined on the right



**Department of Ophthalmology at a Glance:** New York Eye and Ear Infirmary of Mount Sinai (NYEE) and The Mount Sinai Hospital (MSH)/Icahn School of Medicine at Mount Sinai




- Locations**
- 1 New York Eye and Ear Infirmary of Mount Sinai**  
310 East 14th Street  
New York, NY 10003
  - 2 NYEE-East 102nd Street**  
17 East 102nd Street  
New York, NY 10029
  - 3 NYEE-East 85th Street**  
234 East 85th Street  
New York, NY 10028
  - 4 NYEE-Columbus Circle**  
200 West 57th Street  
New York, NY 10019
  - 5 NYEE-Tribeca**  
77 Worth Street  
New York, NY 10013
  - 6 NYEE-Midwood**  
1630 East 15th Street  
Brooklyn, NY 11229
  - 7 NYEE-Mineola**  
200 Old Country Road  
Mineola, NY 11501
  - 8 NYEE After-Hours Emergency Service at MSBI ED**  
281 1st Avenue  
New York, NY 10003



- Affiliated Clinical Sites**
- 9 Mount Sinai Queens**  
25-10 30th Avenue  
Long Island City, NY 11102
  - 10 Mount Sinai Morningside**  
440 West 114th Street  
New York, NY 10025
- Affiliated Teaching Institutions**
- 11 James J. Peters VA Medical Center**  
130 West Kingsbridge Road  
Bronx, NY 10468
  - 12 NYC Health+Hospitals/Elmhurst**  
79-01 Broadway  
Queens, NY 11373
  - 13 Mount Sinai-Union Square**  
10 Union Square East  
New York, NY 10003

**FACULTY NEWS: ACCOLADES**



**Bo Chen, PhD**  
The Icahn School of Medicine at Mount Sinai conferred on Dr. Chen the McGraw Family Foundation Professorship in the Department of Ophthalmology. NYEE and Mount Sinai are grateful for the ongoing support of the Harold W. McGraw, Jr. Family Foundation and its generous donation to establish an endowed professorship in the Department of Ophthalmology to support neuroregeneration research. Considered one of the most prestigious honors in academic medicine, this endowed professorship will enable NYEE to continue to advance its mission of groundbreaking research, education, and clinical care. Dr. Chen received his PhD from the University of Miami School of Medicine and completed his postdoctoral training at Harvard Medical School. NYEE proudly acknowledges the impact its donors have in enabling the institution to achieve its overarching mission, and is immensely grateful for the support of its partners in advancing sight-saving therapies to improve quality of life.



**Richard B. Rosen, MD, FARVO**  
Dr. Rosen accepted the 2022 ARVO Gold Fellow Award for his longstanding commitment to ophthalmology research, furthering ARVO's vision "to advance research worldwide into understanding the visual system and preventing, treating, and curing its disorders." An internationally renowned researcher and lecturer, Dr. Rosen joined NYEE in 1989. Under his leadership, NYEE established one of the most advanced imaging centers in the country, dedicated to the application of novel technologies to address clinical challenges, including high-frequency and 3D ultrasound, macular pigment densitometry, retinal and choroidal blood flow monitoring, retinal oximetry, and metabolic imaging, as well as clinical microscopy. Chief of the Retina Service for the Mount Sinai Health System, Dr. Rosen earned his MD from the University of Miami School of Medicine and completed his ophthalmology residency and vitreo-retinal fellowship at NYEE.



**Paul A. Sidoti, MD**  
A faculty leader at NYEE for more than 24 years, Dr. Sidoti was recognized by the American Glaucoma Society with a 2022 Outstanding Educator Award. Dr. Sidoti has been instrumental in the growth of NYEE's national and international reputation as one of the top teaching hospitals for ophthalmology, introducing many new concepts into the training program, including surgical simulation and an expanded wet-lab experience in the resident surgical curriculum. As Chief of the Glaucoma Service and Deputy Chair for Education for the Mount Sinai Health System's Department of Ophthalmology, he has helped to orchestrate the ongoing integration of The Mount Sinai Hospital and NYEE programs into the country's largest ophthalmology residency program. Dr. Sidoti completed his residency at NYEE and a clinical/research fellowship in glaucoma at the Doheny Eye Institute/University of Southern California School of Medicine.



## FACULTY NEWS: PROMOTIONS



### **Rudrani Banik, MD, Co-Director, Neuro-Ophthalmology Clinic, NYEE**

With a deep passion for education, Dr. Banik combines her clinical activities with teaching and research. A recipient of NYEE's Attending of the Year Resident Teaching Award in 2005, 2010, and 2014, Dr. Banik has served as Principal Investigator on notable multicenter clinical trials in neuro-ophthalmology, has authored numerous articles in the field, and has presented at national and international meetings. Dr. Banik completed her residency training in ophthalmology at the University of California, Irvine, followed by fellowship training in neuro-ophthalmology at the prestigious Wilmer Eye Institute at Johns Hopkins University.



### **Valerie I. Elmalem, MD, Co-Director, Neuro-Ophthalmology Clinic, NYEE**

Fellowship-trained in both neuro-ophthalmology and orbital and ophthalmic plastic surgery, Dr. Elmalem has a special interest in resident education. She will continue to work on improving clinical operations and patient care delivery in the neuro-ophthalmology clinic, while ensuring that residents receive an integrated training curriculum that provides them with unparalleled experience in clinical and surgical care as well as research. She completed her residency and fellowship in neuro-ophthalmology at Emory University School of Medicine, Emory Eye Center, followed by a fellowship in oculoplastics and orbital surgery at the Medical College of Wisconsin.



### **Gautam Kamthan, MD, Associate Director of Cataract Surgical Training, NYEE**

A board certified medical and surgical ophthalmologist, Dr. Kamthan specializes in laser and refractive cataract surgery and micro-invasive glaucoma surgery. As an Assistant Professor of Ophthalmology at the Icahn School of Medicine at Mount Sinai, he is involved in surgical training across NYEE's numerous locations, and was awarded its most prestigious teaching award in 2021, the Jorge N. Buxton MD Microsurgical Teaching Award. In his role as the Assistant Director for Ophthalmic Innovation and Technology, his research includes development of the only surgical robot for Ophthalmology in the U.S. Dr. Kamthan received his medical degree from the Icahn Mount Sinai with honors and completed his residency at The Mount Sinai Hospital.



### **Gareth M. C. Lema, MD, PhD, Vice Chair for Quality, Safety, and Experience, Department of Ophthalmology, NYEE**

Dr. Lema is expanding his focus on Quality, Safety, and Experience at The Mount Sinai Hospital to the Department of Ophthalmology's numerous locations across the Mount Sinai Health System. He will apply his problem-solving skills to develop standardized and comprehensive processes and programs that will continue to ensure the safety of the care we deliver and enhance the experience of not just patients, but our physicians and staff. A fellowship-trained retina specialist, Dr. Lema completed his residency at the University at Buffalo, Ross Eye Institute, followed by a vitreo-retinal fellowship at the University of Rochester's Flaum Eye Institute.



### **Tak Yee Tania Tai, MD, Vice Chair for Clinical Operations, Department of Ophthalmology, NYEE**

As Director of the Glaucoma Clinic and Microsurgical Training at NYEE, Dr. Tai will apply her clinical and teaching expertise to improve the efficiency and effectiveness of clinical operations throughout the multiple practice sites in the Department of Ophthalmology. Working in conjunction with the System/Site Chairs, Vice Chair for Quality, Safety, and Experience, and senior management team, she will ensure delivery of high quality and efficient patient care, technical training/education for staff, and adherence to national guidelines/benchmarks. Dr. Tai completed her residency at the Jules Stein Eye Institute, UCLA, followed by a glaucoma fellowship at Wills Eye Hospital.

## FACULTY NEWS: NEW RECRUITS



### **Nazanin Barzideh, MD**

Dr. Barzideh joins the Department as the Medical Director of the NYEE-Mineola faculty practice satellite office, helping to drive patient volume and play an essential role in the planned relocation to a new facility later this year. As a certified investigator for the Diabetic Retinopathy Clinical Research Network, Dr. Barzideh enjoys applying the newest scientific advancements and cutting-edge technology in the treatment of retinal diseases. Dr. Barzideh completed her ophthalmology residency at SUNY Downstate Medical Center in Brooklyn—where she served as a chief resident in her final year—and a vitreo-retinal fellowship at the National Retina Institute in Maryland.



### **Christina Cherny, OD**

A specialist in complex, comprehensive optometric care with an emphasis on ocular disease and contact lenses, Dr. Cherny brings expertise in emergent care, vision rehabilitation, and the management of patients with a wide variety of ophthalmic conditions. Dr. Cherny completed her residency in ocular disease and cornea/contact lenses at Massachusetts Eye and Ear in Boston, and earned her Doctor of Optometry from SUNY College of Optometry in New York City, where she also received the Chancellor's Award for Student Excellence.




### **Alberto G. Distefano, MD**

Dr. Distefano joins the Department as Director of Oculoplastic, Orbital, and Reconstructive Surgery at The Mount Sinai Hospital. An author of many peer-reviewed articles and chapters, Dr. Distefano's clinical focus includes diagnosis and management of optic nerve and brain disorders affecting vision, and management of a wide range of eyelid and orbital conditions in adults and children. He is leaving his position as an Assistant Professor of Ophthalmology at the Boston University School of Medicine. After completing his residency in ophthalmology at the Icahn School of Medicine at Mount Sinai, Dr. Distefano pursued a dual fellowship in oculoplastic and reconstructive surgery at Yale School of Medicine and in neuro-ophthalmology at the Bascom Palmer Eye Institute.



### **Varun Kumar, PhD**

As a new Assistant Professor of Ophthalmology, and Pharmacological Sciences, at the Icahn School of Medicine at Mount Sinai, Dr. Kumar will continue his research involving endoplasmic reticulum and mitochondria stress response—and their crosstalk—in Fuchs' endothelial corneal dystrophy. A recipient of the 2021 Santel, Inc./ARVO Foundation and NEI K99/ROO Early Career Award, Dr. Kumar joins the department from Schepens Eye Research Institute at Massachusetts Eye and Ear in Boston. He completed his postdoctoral research fellowships in ophthalmology at Harvard and Stanford universities, and received his PhD in neuroscience at Kent State University in Ohio.



### **Rochelle Fleisher, OD**

Dr. Fleisher joins NYEE from The Eye Institute at Pennsylvania College of Optometry, Salus University in Philadelphia. During her residency, she specialized in providing comprehensive primary eye care to inner-city patient populations, and managed patients with a wide variety of routine and emergent ophthalmic conditions. A recipient of the Ira Goldfarb Memorial Award for Excellence in Low Vision, Dr. Fleisher earned her Doctor of Optometry from SUNY College of Optometry in New York City.



## NYEE RESIDENTS

### PGY-4

Jorge Andrade Romo, MD  
Laura Barna, MD  
Nitin Chopra, MD  
Jeanette Du, MD  
Mona Fayad, MD  
Giselle Lynch, MD  
Michael Schatz, MD

### PGY-3

Maria Castanos Toral, MD  
Christina Dowell, MD  
Elaine Han, MD  
Kyle Hirabayashi, MD  
Grant Hopping, MD  
Jerry Hsu, MD  
Sefy Paulose, MD  
Gabriel Shakarov, MD  
Daniel Vail, MD  
Meena Zakher, MD

### PGY-2

Aaron Brown, MD  
Chih-Chiun Chang, MD  
Allen Costa, MD  
Anthony Fam, MD  
Ha Min Kim, MD  
David Merriott, MD  
Devayu Parikh, MD  
Jackson Scharf, MD  
Khushali Shah, MD  
Davis Zhou, MD

## MSH RESIDENTS

### PGY-4

Jeffrey Brown, MD  
Jonathan Levenson, MD  
Heather McGowan, PhD, MD  
Nancy Worley, MD

## NYEE FELLOWS

Nisha Dhawlikar, MD (Cornea)  
Artur Filipowicz, DO (Glaucoma)  
Julia Fallon, MD (Vitreo-Retina)  
Yafeng Li, MD (Vitreo-Retina)

Michael Park, MD (Vitreo-Retina)  
Nilesh Kaushik Raval, MD  
(Vitreo-Retina)

## ICAHN SCHOOL OF MEDICINE AT MOUNT SINAI DEPARTMENTAL LEADERSHIP

**James C. Tsai, MD, MBA**  
President, NYEE  
Chair, Department of Ophthalmology,  
Icahn Mount Sinai and MSHS

**Louis R. Pasquale, MD, FARVO**  
Chair, Department of Ophthalmology,  
MSH and MSQ  
Deputy Chair for Research and  
Director, Mount Sinai/NYEE Eye  
and Vision Research Institute,  
Icahn Mount Sinai

**Paul A. Sidoti, MD**  
Chair, Department of Ophthalmology,  
NYEE  
Deputy Chair for Education,  
Department of Ophthalmology,  
Icahn Mount Sinai  
Chief, Glaucoma, MSHS

**Mark Kupersmith, MD**  
Vice Chair, Translational  
Ophthalmology Research,  
Icahn Mount Sinai  
Chief, Neuro-Ophthalmology, MSHS

**Richard B. Rosen, MD, FARVO**  
Vice Chair and Director of Ophthalmic  
Research, NYEE  
Chief, Retina Service, MSHS

**Salvatore Loiacono, Jr., MPA**  
Deputy Chair, Finance and  
Administration, MSHS  
Vice President for Ophthalmology  
Services, NYEE

**Elizabeth Sellman**  
Chief Operating Officer, MSBI and  
NYEE

**Tamiesha Frempong, MD, MPH**  
Vice Chair, Diversity and Inclusion,  
Department of Ophthalmology,  
Icahn Mount Sinai

**Sandra K. Masur, PhD**  
Vice Chair, Academic Development and  
Mentoring, Department of Ophthalmology,  
Icahn Mount Sinai

**Anita Gupta, MD**  
Vice Chair, Professional Development,  
Department of Ophthalmology,  
Icahn Mount Sinai

**Alon Harris, MS, PhD, FARVO**  
Director, Ophthalmic Vascular  
Diagnostic and Research Program, MSH  
Vice Chair, International Research and  
Academic Affairs and Chair, Promotion  
and Tenure Committee,  
Department of Ophthalmology,  
Icahn Mount Sinai

**Gareth M. C. Lema, MD, PhD**  
Vice Chair, Quality, Safety and Experience,  
Department of Ophthalmology, NYEE

**Tak Yee Tania Tai, MD**  
Vice Chair, Clinical Operations,  
Department of Ophthalmology, NYEE

**Paul S. Lee, MD**  
President, NYEE/MSH Department of  
Ophthalmology Alumni Association

**Nisha Chadha, MD**  
Director, Medical Student Education,  
Department of Ophthalmology,  
Icahn Mount Sinai

**Tsontcho A. Ianchulev, MD, MPH**  
Director, Ophthalmic Innovation and  
Technology, NYEE

## RESIDENCY AND FELLOWSHIP EDUCATION

**Sumayya Ahmad, MD**  
Director, Ophthalmology  
Residency Program, MSH

**Masako Chen, MD**  
Assistant Director, Ophthalmology  
Residency Program, NYEE

**Tamiesha Frempong, MD, MPH**  
Assistant Director, Ophthalmology  
Residency Program, Elmhurst  
Hospital

**Meenakashi Gupta, MD**  
Director, Resident and Fellow  
Wellness, Department of  
Ophthalmology, NYEE

**Gautam Kamthan, MD**  
Assistant Director, Ophthalmic  
Innovation and Technology, NYEE  
Associate Director, Cataract Surgical  
Training, NYEE

**Gennady Landa, MD**  
Associate Director, Vitreo-Retinal  
Fellowship Program, NYEE

**Paul S. Lee, MD**  
Associate Director, Ophthalmology  
Residency Program, NYEE

**Harsha S. Reddy, MD**  
Director, Ophthalmology Residency  
Program, NYEE

**Richard B. Rosen, MD, FARVO**  
Director, Vitreo-Retinal  
Fellowship Program, NYEE

**Tak Yee Tania Tai, MD**  
Director, Microsurgical Education,  
Department of Ophthalmology, NYEE

**Kateki Vinod, MD**  
Director, Glaucoma Fellowship  
Program, NYEE

**Angie E. Wen, MD**  
Director, Cornea and External  
Diseases Fellowship Program, NYEE

## CLINICAL DIVISIONS AT MOUNT SINAI HEALTH SYSTEM FACULTY PRACTICES

### Cataract Surgery

**Richard Koplun, MD**  
Co-Director, Cataract Service,  
NYEE

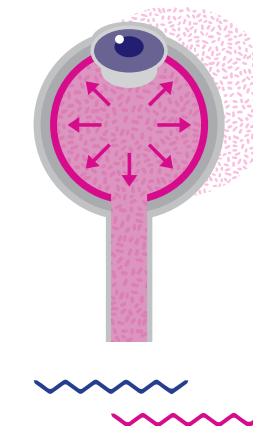
**Kira Manusis, MD**  
Co-Director, Cataract Service,  
NYEE

**Sumayya Ahmad, MD**  
**Nisha Chadha, MD**  
**Masako Chen, MD**  
**Anita Gupta, MD**  
**David J. Harris, MD**  
**Tsontcho A. Ianchulev, MD, MPH**  
**Gennady Landa, MD**  
**Rachel Lee, MD**  
**Neha Shaik, MD**  
**Tak Yee Tania Tai, MD**  
**Angie E. Wen, MD**  
**Sze H. Wong, MD**

### Cornea, External Diseases, and Refractive Surgery

**Anita Gupta, MD**  
Director, Cornea and External  
Diseases, NYEE

**Sumayya Ahmad, MD**  
**Masako Chen, MD**  
**David J. Harris, MD**  
**Kira Manusis, MD**  
**Neha Shaik, MD**  
**Angie E. Wen, MD**



## Eye Trauma

**John Aljian, MD**  
Director, Anterior Segment Trauma  
Service, NYEE

**Ronald C. Gentile, MD**  
Director, Posterior Segment  
Trauma Service, NYEE

**Harsha S. Reddy, MD**  
Director, Oculoplastic Trauma, NYEE

**Sumayya Ahmad, MD**  
**Masako Chen, MD**  
**Mary-Abigail Craven, MD**  
**Avnish Deobhakta, MD**  
**Alberto G. Distefano, MD**  
**Valerie I. Elmalem, MD**  
**Robin N. Ginsburg, MD**  
**Anita Gupta, MD**  
**Meenakashi Gupta, MD**  
**David J. Harris, MD**  
**Gennady Landa, MD**  
**Gareth M. C. Lema, MD, PhD**  
**Kira Manusis, MD**  
**Trisha Mor, MD**  
**Richard B. Rosen, MD, FARVO**  
**Neha Shaik, MD**  
**Angie E. Wen, MD**

## Glaucoma

**Paul A. Sidoti, MD**  
Chief, Glaucoma, MSHS

**Tak Yee Tania Tai, MD**  
Director, Glaucoma Clinic, NYEE

**Nisha Chadha, MD**  
**Donna Gagliuso, MD**  
**Tsontcho A. Ianchulev, MD, MPH**  
**Paul S. Lee, MD**  
**Rachel H. Lee, MD**  
**Louis R. Pasquale, MD, FARVO**  
**James C. Tsai, MD, MBA**  
**Kateki Vinod, MD**  
**Sze H. Wong, MD**



## Neuro-Ophthalmology

**Mark Kupersmith, MD**  
Chief, Neuro-Ophthalmology, MSHS

**Rudrani Banik, MD**  
Co-Director, Neuro-Ophthalmology  
Clinic, NYEE

**Valerie I. Elmalem, MD**  
Co-Director, Neuro-Ophthalmology  
Clinic, NYEE

**Mary-Abigail Craven, MD**  
**Alberto G. Distefano, MD**

## Ocular Oncology

**Paul T. Finger, MD**  
Director, Ocular Oncology, NYEE

**Ekaterina Semenova, MD, PhD**

## Ophthalmic Pathology

**Jodi Sassoon, MD**  
Chair, Pathology, NYEE

**Alan Friedman, MD**  
**Codrin E. Iacob, MD, FCAP**

## Oculoplastic, Orbital, and Reconstructive Surgery

**Alberto G. Distefano, MD**  
Director, Oculoplastic, Orbital, and  
Reconstructive Surgery, MSH

**Harsha S. Reddy, MD**  
Director, Oculoplastic, Orbital, and  
Reconstructive Surgery, NYEE  
Site Director, Department of  
Ophthalmology, MSBI

**Mary-Abigail Craven, MD**  
**Monica Dweck, MD**  
**Valerie I. Elmalem, MD**

## Pediatric Ophthalmology and Strabismus

**Tamiesha Frempong, MD, MPH**  
**Thomas J. Quehl, MD**  
**Edward Raab, MD**

## Primary Care Ophthalmology/ Optometry

**Masako Chen, MD**  
Director, Comprehensive  
Ophthalmology  
Clinic, NYEE

**Christina Cherny, OD**  
**Kristina Creadore, OD**  
**Rochelle Fleisher, OD**  
**Karen Hendler-Goldberg, MD**  
**Brenda Hahn, OD**  
**Shreya Jayasimha, OD**  
**Lisa Kingsly, OD**  
**Anthony Nguyen, OD**  
**Leannza Tang, OD**

## Retina

**Richard B. Rosen, MD, FARVO**  
Chief, Retina, MSHS

**Robin N. Ginsburg, MD**  
Director, Retina, MSH

**Gennady Landa, MD**  
Director, Retina, NYEE

**Nazanin Barzideh, MD**  
**Avnish Deobhakta, MD**  
**Meenakashi Gupta, MD**  
**Gareth M. C. Lema, MD, PhD**  
**Trisha Mor, MD**  
**R. Theodore Smith, MD, PhD**

## Uveitis and Ocular Immunology

**Varun K. Pawar, MD**

## Basic Science/Translational Research Faculty

**Louis R. Pasquale, MD, FARVO**  
Director, Mount Sinai/NYEE Eye  
and Vision Research Institute,  
Icahn Mount Sinai

**Timothy A. Blenkinsop, PhD**  
**Bo Chen, PhD**  
**Yuen Ping Toco Chui, PhD**  
**Alon Harris, MS, PhD, FARVO**  
**Varun Kumar, PhD**  
**Jun Lin, MD, PhD**  
**Sandra Masur, PhD**  
**Richard B. Rosen, MD**  
**R. Theodore Smith, MD, PhD**  
**Jose Mario Wolosin, PhD**

## Affiliated Leadership

**Douglas F. Buxton, MD**  
President, Jorge N. Buxton, MD,  
and Douglas F. Buxton, MD,  
Microsurgical Education Fund

**Paul S. Lee, MD**  
Chief of Ophthalmology,  
James J. Peters VA Medical Center

**Robert Fischer, MD**  
Director of Ophthalmology, Elmhurst  
Hospital

**Michelle Rhee, MD**  
Associate Director of  
Ophthalmology, Elmhurst Hospital

**Icahn Mount Sinai**  
Icahn School of Medicine at Mount Sinai  
**MSHS**  
Mount Sinai Health System  
**MSH**  
The Mount Sinai Hospital  
**MSBI**  
Mount Sinai Beth Israel  
**MSM**  
Mount Sinai Morningside  
**MSQ**  
Mount Sinai Queens  
**MSW**  
Mount Sinai West  
**NYEE**  
New York Eye and Ear Infirmary of  
Mount Sinai



Illustration and Graphic design by  
TJASART, Tjaša Žurga Žabkar s.p.







Specialty Report | FALL 2022 | [www.nyee.edu](http://www.nyee.edu)



**WE FIND A WAY**



New York  
Eye and Ear  
Infirmary of  
**Mount  
Sinai**